

11-3-2006

Dermatofibrosarcoma protuberans: Surgical excision versus Mohs surgery

Connie Chung
Yale University

Follow this and additional works at: <http://elischolar.library.yale.edu/ymtdl>

Recommended Citation

Chung, Connie, "Dermatofibrosarcoma protuberans: Surgical excision versus Mohs surgery" (2006). *Yale Medicine Thesis Digital Library*. 226.
<http://elischolar.library.yale.edu/ymtdl/226>

This Open Access Thesis is brought to you for free and open access by the School of Medicine at EliScholar – A Digital Platform for Scholarly Publishing at Yale. It has been accepted for inclusion in Yale Medicine Thesis Digital Library by an authorized administrator of EliScholar – A Digital Platform for Scholarly Publishing at Yale. For more information, please contact elischolar@yale.edu.

Dermatofibrosarcoma protuberans: Surgical excision versus Mohs surgery

A Thesis Submitted to the
Yale University School of Medicine
in Partial Fulfillment of the Requirements for the
Degree of Doctor of Medicine

by

Connie Chung

2006

DERMATOFIBROSARCOMA PROTUBERANS: SURGICAL EXCISION VERSUS MOHS SURGERY. Connie Chung, Mariel Eliza, Sumaira Aasi, David Leffell, and Deepak Narayan. Section of Plastic Surgery and Section of Dermatologic Surgery and Cutaneous Oncology, Department of Surgery and Department of Dermatology, Yale University, School of Medicine, New Haven, CT.

The purpose of this project was to compare the recurrence rates of dermatofibrosarcoma protuberans (DFSP) treated with surgical excision (SE) and Mohs surgery (MS) at Yale. Patients were identified through the dermatopathology laboratory database and stratified by treatment. The following information was collected: age at onset, sex, disease state (primary presentation versus recurrence), tumor site, preoperative tumor size, postoperative defect size, excisional margin, duration of follow-up, and recurrence after treatment. Of the 30 patients, 14 were in the SE group, and 16 were in the MS group. There were no recurrences in the SE group, and there was 1 recurrence (6%) in the MS group, which occurred 37 months post-operatively. The average area of the tumors were $12.1 \text{ cm}^2 \pm 16.1$ (SE) and $5.3 \text{ cm}^2 \pm 5.9$ (MS), and the mean excisional margins were $3.8 \text{ cm} \pm 1.6$ (SE) and $1.4 \text{ cm} \pm 0.5$ (MS). The mean duration of follow-up in the SE group was $33 \text{ months} \pm 41$ (range: 1-116 months), and the mean duration of follow-up in the MS group was $26 \text{ months} \pm 25$ (range: 2 to 69 months.) Although the MS group had a higher recurrence rate than the SE group, using the recurrence rates to make meaningful conclusions about the efficacy of the two treatment modalities is limited by the small n , lack of randomization to either procedure, and duration of follow-up. Once these issues are addressed, recurrence rates must also be adjusted for patient and tumor characteristics, that are associated with higher recurrence rates.

Acknowledgements

10,000 thank you's to Dr. Narayan for the generous guidance, patience, encouragement, and laughs that have sustained me throughout this endeavor. I also thank the Office of Student Research and the Doris Duke Charitable Foundation for allowing a seed to blossom.

Table of Contents

Introduction	1
Statement of purpose	13
Methods	14
Results	15
Discussion	18
References	25

Introduction

Dermatofibrosarcoma protuberans (DFSP) is a malignant soft tissue neoplasm initially described in 1890 by Taylor, who wrote of a cutaneous tumor that looked like a keloid and had the potential to recur. (1) More than 30 years later in 1924, Darier and Ferrand further characterized this clinical entity and named it “progressive and recurrent dermatofibroma.” (2) In the following year, Hoffmann coined the term “dermatofibrosarcoma protuberans.” (3) Today, DFSP remains a distinct entity marked by a triad of characteristics: its rarity, its slow growth, and its infiltrative nature.

On the whole, malignant soft tissue tumors are relatively rarer than carcinomas and other tumors, so they account for only 0.8% to 1% of all cancers diagnosed each year. (4) Therefore, it is very difficult to determine the frequency and incidence of DFSP, and there are only a few large series that report the experience of a single institution over a period of time. The earliest attempt found in the literature was in 1948 by Pack and Tabah, who had 39 cases in 50,000 patients admitted to their mixed tumor service over 29 years. (5) They calculated a frequency of DFSP of less than 0.1% of all tumors and an incidence of about 2 cases of DFSP a year. In 1967, McPeak, Cruz, and Nicastrì added 86 more patients to this same service, and they attributed the threefold increase in incidence to a rise in the total number of patients seen, as well as to improved recognition of the distinct features of DFSP. (6)

More recently in the eighties, Bendix-Hansen and his group had 16 cases in 261 patients with soft tissue sarcomas over 16 years, and they calculated a frequency of DFSP

of 7% of all soft tissue sarcomas and an incidence of 0.8 cases of DFSP per one million persons per year. (7) Finally, Chang et al. had 60 cases of DFSP treated between 1968 and 2001, compared to approximately 100 patients with any type of soft tissue sarcoma who were treated each year at their institution (University of Illinois-Chicago), and therefore, DFSP accounted for approximately 1.8% of all soft tissue sarcomas encountered. (8)

Although the appearance of DFSP varies with the stage of the disease, DFSP initially presents as a slightly raised sclerotic plaque-like mass or small nipple-like projection on the surface of previously healthy skin, area of repeated trauma, vaccination site, irradiated skin, or scar. (9) While firmly fixed to the overlying skin, DFSP is not attached to the underlying deeper structures, but there may be multiple satellite nodules at the periphery of the main lesion as well. (10) Pressure on the surface of the lesion causes blanching (6), and the tumor is usually skin-colored with a brown-yellow or red tinge. (11) (Figure 1) Occasionally, this discoloration precedes the development of a definite tumefaction. (12) Therefore, this type of presentation can be misinterpreted as a keloid. (13) Additionally, DFSP has been compared clinically with a morphea-type of basal cell carcinoma and scleroderma. (4)

DFSP lesions typically arise on the trunk of the body, and in a series of 853 patients, the authors observed the following site distribution: trunk, 47%; lower extremity, 20%; upper extremity, 18%; and head and neck, 14%. (4) Moreover, DFSP is slightly more common in men than in women, and in a series of 264 patients, the authors

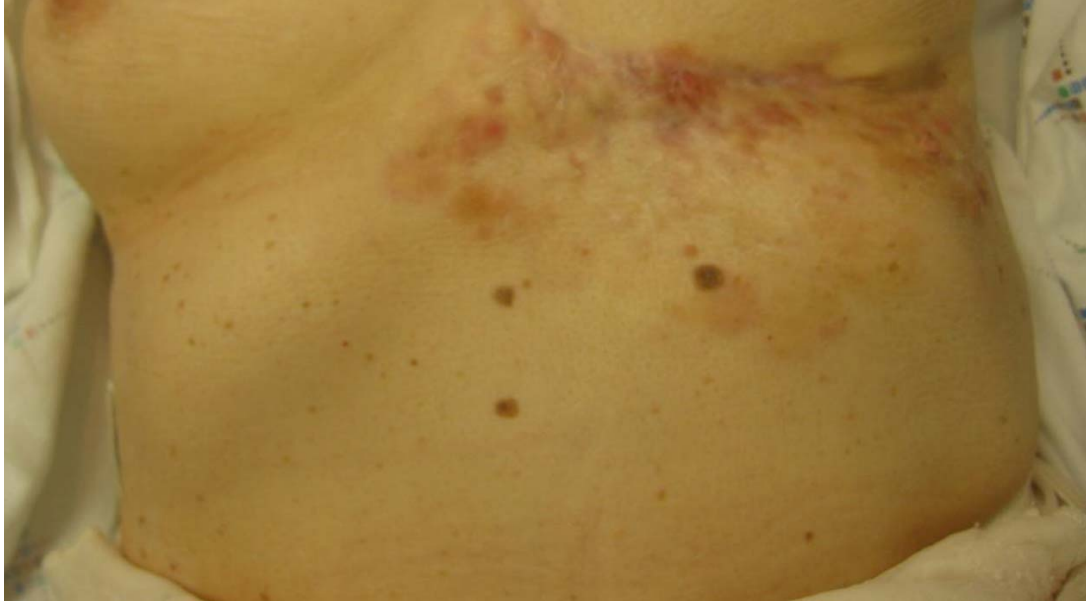

Figure 1: An indurated plaque with firm, irregular nodules varying in color from flesh to reddish brown.

observed a male-to-female ratio of approximately 3:2. (14) Known to arise in patients of widely varying ages, DFSP has an age distribution in the literature that ranges from six to 87 years of age, but the majority of patients present during early- to mid- adult life. (15) There are a few reports citing lesions that presented in children, and there are 5 reported cases of DFSP being present since birth. (1, 5, 16)

DFSP is characteristically slow growing, resulting in a long latency period and lesions that persist for years without symptoms. (10) Therefore, in 3 earlier series, the majority of patients did not seek medical care for at least 3 years. (6, 12, 17) However, in 2 more current series, the delay was usually less than 3 years. (7, 18) Eventually, DFSP enters a rapid growth phase, producing pain or tenderness that usually prompts patients to seek medical evaluation of the lesion. (10) As the rapidly growing mass enlarges, the

overlying skin stretches and thins, which can lead to ulcerations and bleeding, and the lesion becomes fixed to the deep subcutaneous structures and fascial planes. (10)

Moreover, the satellite nodules at the periphery of the lesion coalesce into a larger mass to obtain its typical “protuberant” appearance. (10) Although areas of extremely large and neglected tumors may infarct and undergo spontaneous involution, deeper areas will continue to grow and invade the surrounding tissue. (10) However, despite the enormous size of some DFSP tumors, patients may appear well and without the signs of cachexia that are commonly associated with other advanced cancers. (4)

The size of DFSP lesions at presentation, then, varies widely. In a series of 159 patients treated between 1950 and 1998, the authors found that the majority of lesions were <5 cm in maximum diameter, but the lesion sizes had the following distribution: <5cm, 134 patients (84%); 5-10 cm, 21 patients (13%); and >10 cm, 4 patients (3%). (15) Of note, the authors found that the DFSP lesions were predominantly superficial; 121 patients (77%) had superficial lesions and 36 patients (22%) had lesions that had invaded deeper structures. The depth of invasion was not reported in the remaining 2 patients (1%).

Biopsies of DFSP reveal gray-white, rubbery, fibrous tissue that makes up a solitary, multinodular, protuberant mass, and it is important to note that the mass appears deceptively well-circumscribed, because DFSP is characterized by an infiltrative growth pattern, and multiple finger-like projections can extend microscopically beyond the visible margins. (10) In 1962, Taylor and Helwig meticulously described the

microscopic features of DFSP with a series of 115 cases, and histologically, the central cellular portion of DFSP appears as a uniform population of atypical spindle-shaped cells that show little pleomorphism or mitotic activity. (17) They observed that these cells organize themselves radially around the vasculature in a distinct, but monotonous, storiform or cartwheel pattern. (Figure 2)

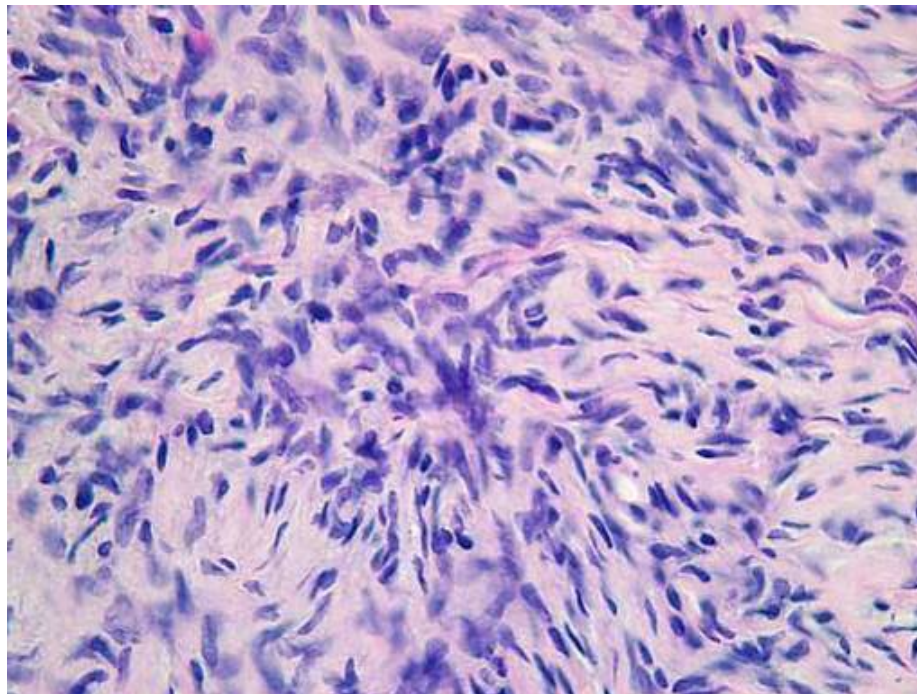


Figure 2: Cells radiate from a central hub of fibrous tissue forming a cartwheel or storiform pattern.

During the initial period of slow growth, DFSP grows laterally along the interfascicular spaces of the reticular dermis, so at the leading edge of the tumor, attenuated malignant cells blend imperceptibly with dermal fibroblasts, making the interface between tumor and normal tissue difficult to distinguish. (10) As the lesion

progresses, the tumor cells infiltrate the subcutaneous fat in an intricate, asymmetrical pattern, resulting in a honeycomb pattern of entrapped fat cells. (10) (Figure 3) Vertical

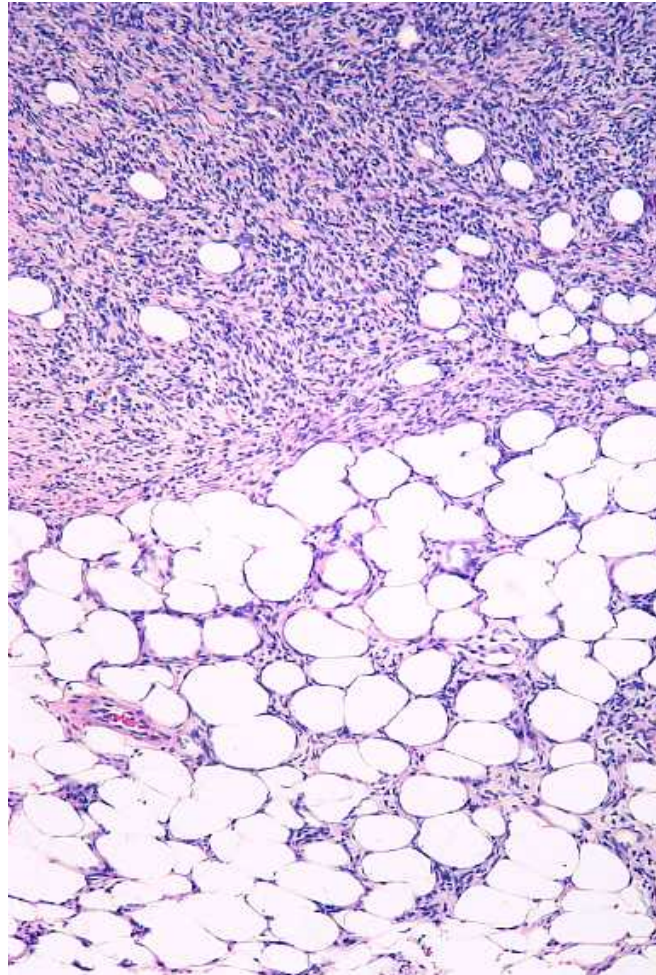


Figure 3: DFSP extension into the subcutaneous fat results in a lacy or honeycomb pattern.

infiltration occurs during the period of rapid growth, resulting in ulceration as DFSP spreads from the epidermis along the fascial planes of skeletal muscle. (10) However, there are several unusual histological variants (Table 1), and the differential contains more than 10 diagnostic considerations (Table 2). (11)

Table 1: DFSP variants

- Atropic DFSP
(morphea-like plaques)
- DFSP with giant cell angiofibroma
- Fibrosarcomatous DFSP
(sarcomatous areas)
- Myxoid DFSP
- Palisaded DFSP
(reminiscent of schwannoma)
- Pigmented DFSP
(Bednar tumor)
- Sclerosing DFSP
(abundant sclerotic tissue)

Table 2: Differential Diagnosis for DFSP

- Atypical fibroxanthoma
- Classic fibrosarcoma
- Fasciitis
- Myxofibrosarcoma
- Myxoid liposarcoma
- Cellular fibrous histiocytoma
- CD34+ benign fibrous hystiocytoma
- Dermal dendrocytic hamartoma
- Dermatomyofibroma
- Desmoplastic melanoma
- Neurofibroma
- Plexiform fibrohistiocytic tumor

It is important to note that regional and distant metastasis are rare despite the aggressive local invasiveness of DFSP. In the early literature, the true incidence of metastases is difficult to assess because of the inclusion of other spindle cell tumors. (10) However, a recent study that used stricter criteria found that the risk for development of metastatic disease is approximately 5%. (14) In this series of 913 cases of DFSP, 11 patients, or 1%, had regional lymph node metastasis, and 37 patients, or 4%, had distant metastasis. Moreover, the overwhelming majority of reported metastases of DFSP follow multiple local recurrences, and of these metastases, approximately 75% are hematogenous spread to the lungs, with the remaining 25% being lymphatic spread to the regional lymph nodes. (4) Rare metastases to the brain, bone, and heart have also been documented. (4) Increased cellularity and mitotic activity are important factors in enhancing the metastatic potential of DFSP. (19)

Differentiation of DFSP, therefore, is aided by immunostaining with CD34 and Factor XIIIa. CD34 is a 110-kD glycosylated transmembrane protein of unknown function that is raised against the human myeloid leukemia cell line KG1a. (20) In

addition to being identified on vascular endothelial cells, their derivative tumors, and dendritic interstitial cells within the gastrointestinal tract (21, 22), CD34 has also been identified in 10 to 30% of the dendritic interstitial cells in the reticular dermis, as well as in spindle cells in and around the eccrine glands, and perifollicular spindle cells in the midportion of the hair follicle. (23) However, dendritic interstitial cells in the upper papillary dermis, which are cytologically similar to those found in the reticular dermis, are immunophenotypically distinct, so they are CD34 negative but factor XIIIa positive. (24) Factor XIIIa is a tetrameric protein also known as fibrin-stabilizing factor and plays a key role in the coagulation system. (25) While DFSP stains positively for CD34 and negatively for factor XIIIa, dermatofibromas, or benign fibrous histiocytomas, stain negatively for CD34 and positively for factor XIIIa. (26) This distinction is particularly clinically relevant in terms of treatment.

Three other novel markers can also help distinguish DFSP lesions from dermatofibromas. Dermatofibromas tend to stain positively for CD44, a membrane glycoprotein thought to be the cell surface receptor for hyaluronate, the major component of the extracellular matrix, while DFSPs tend to have absent or significantly reduced CD44 immunostaining. (27) Another marker that can help distinguish between DFSP lesions and dermatofibromas is p75, a low-affinity nerve growth factor receptor. (28) A wide variety of mesenchymal and epithelial tumors stain positively for p75, indicating that p75 expression is not specific to nerve sheath tumors, but in one study, DFSP lesions stained positively for p75 in 69 of 73 DFSP lesions, or 95% of the lesions, while

dermatofibromas had negative immunostaining for p75. (28) Finally, Apo D, which is a 33kDa glycoprotein that acts as a component of the high density lipoprotein structure, demonstrated strong immunoreactivity in 9 of 10 typical DFSP lesions in a study, as well as in 5 of 6 DFSP variants, while immunostains were negative in 16 of 16 dermatofibromas, as well as in 12 of 12 dermatofibroma variants. (29)

Although thought to arise from a dermal stem cell or an undifferentiated mesenchymal cell with fibroblastic, muscular, and neurologic features, the pathogenesis of DFSP is not fully understood. (30) However, Japanese researchers in 2002 demonstrated that chromosomal translocations or ring chromosomes occur in DFSP through a fusion of chromosome regions 17q22 and 22q13. (31) These gene locations code the alpha chain of type I collagen (COL1A1) and the beta chain of platelet-derived growth factors (PDGF β), and the same abnormality is found in giant cell fibromas. (32) As a result, there is deregulation of PDGF β chain expression, because the ring chromosome expresses a COL1A1-PDGF β fusion protein that binds to the PDGF receptor β protein tyrosine kinase, leading to constant activation and stimulation for growth of DFSP cells. (33, 34)

The extent of deep invasion of DFSP can be evaluated with magnetic resonance imaging (MRI), and Torreggiani et al. applied this technique in a series of patients with large recurrent DFSP lesions. (35) In their study, 10 patients with DFSP underwent MRI, and conventional T1-weighted images revealed the DFSP lesion to be isointense compared with skeletal muscle in 5 of the patients, slightly hypointense in 3 of the

patients, and hyperintense in the remaining 2 patients. Of note, all of the DFSP lesions were hypointense compared with the subcutaneous fat. However, when conventional T2-weighted images were obtained in 6 of the patients, and fast spin-echo T2-weighted images were obtained in the remaining 4 patients, half of the patients had DFSP lesions that had a higher signal intensity than that of subcutaneous fat, and half of the patients had DFSP lesions that had a similar signal intensity than that of subcutaneous fat. On the other hand, computed tomography (CT) is not indicated as an initial diagnostic modality for DFSP lesions, except in rare cases in which one suspects underlying bone involvement. (8) Although DFSP rarely exhibits lymphatic or hematogenous dissemination, the occasional patient with advanced, recurrent, and/or intermediate grade DFSP lesions may have pulmonary metastases, and therefore, it is recommended that these patients receive a chest x-ray. (8)

Although the American Joint Committee on Cancer has not set forth a system specific for the staging of DFSP, it is currently staged in accordance with the American Musculoskeletal Tumor Society (MSTS) staging system, which takes into account tumor grade and compartmentalization. MSTS Stage 1A DFSP tumors are low-grade lesions without extension beyond the subcutaneous compartment, and Stage 1B DFSP tumors are low-grade lesions with extracompartmental extension into the underlying fascia or muscle. (36, 37)

While it is clear that the optimal treatment for DFSP is resection, the literature remains unclear about the optimal mode of resection, and patients may be treated by wide

surgical excision or Mohs micrographic surgery. In both procedures, the characteristic finger-like extensions of DFSP that lie beneath clinically normal appearing skin makes complete removal difficult, and recurrence rates of DFSP for both wide local surgical excision and Mohs micrographic surgery vary widely from study to study.

In wide surgical excision, clinically evident tumor is excised with a rim of normal appearing tissue. This additional margin is removed because the characteristic microscopic extensions of DFSP cannot be visualized or palpated by the surgeon. Therefore, specimens are subsequently evaluated by pathologists. Standard frozen sections are usually cut vertically, as in slicing a loaf of bread, measuring approximately 10 millimicrons (μ) in thickness, and representative vertical sections are examined in each of the 4 quadrants of the specimen (ie. 12, 3, 6, and 9 o'clock positions). (38) If the viewed sections do not show tumor, the margins are called clear. Although other unexamined slices may still contain tumor, it is impractical to examine all of the vertical sections of a specimen; for example, a 5mm long piece of tissue would necessitate the preparation and examination of 5000 individual specimens. Ultimately, less than 1% of the interface between the specimen and the patient is actually examined histologically (39), so standard vertical step sectioning may miss microscopic DFSP. However, tumor recurrence is not correlated with tumor size, but correlated instead with resection margins of the tumor. (40) In a study of 48 patients with DFSP, the authors found a trend toward decreasing recurrence with increasing excision margins; while there was a 41% recurrence rate with margins less than 2 cm, there was a 24% recurrence rate with

margins greater than or equal to 2 cm. (40) Currently, 3 cm margins are recommended in a standard wide surgical excision. (38)

In Mohs micrographic surgery, the dermatologist is both surgeon and pathologist, and the procedure couples serial excision with microscopic examination to trace the tumor. Frederic E. Mohs originated this technique while working as a cancer research assistant during medical school in the early 1930s, serendipitously observing preservation of the microscopic detail of the tissue while testing the irritant effect of an intratumoral injection of 20% zinc chloride. (41) His observation that the tissue appeared as though it had been excised and immersed in a fixative solution gave birth to the idea of excising tumors under microscopic control.

Currently, excision of a layer of the tumor is followed by evaluation of horizontal frozen sections to determine deep tumor margins, allowing preservation of the maximal amount of normal tissue. (42) The tissue layer is 1) divided into smaller specimens, 2) numbered consecutively, 3) inked to distinguish left and right skin edges, and 4) mapped to show the anatomic origin of each specimen. Frozen sections measuring 6-10 microns in thickness are sliced from the bottom and sides of each specimen, stained, and examined under the microscope by the dermatologist. Residual tumor is drawn on the previously drawn map of the tissue layer, and the another tissue layer is removed. This cyclic process of excision, mapping, and microscopic examination is repeated until no residual tumor is found microscopically. (42) (Figure 4) Therefore, almost 100% of the tumor margins are examined histologically. (39)

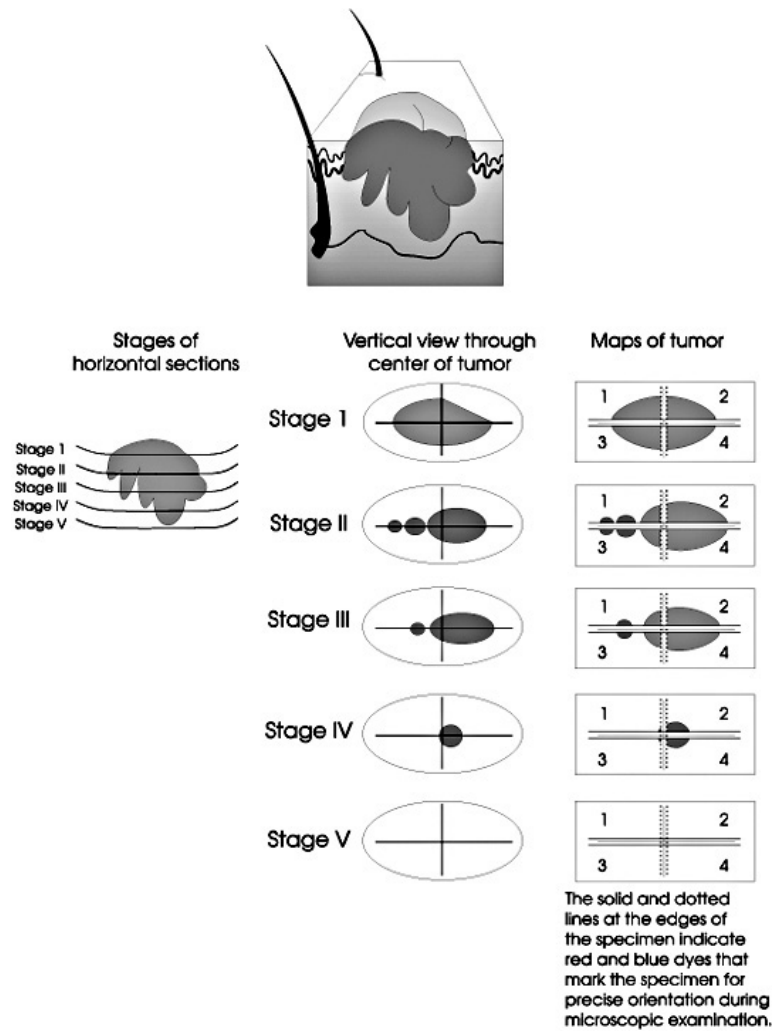


Figure 4: Mohs surgery is a cyclic process of excision, mapping, and microscopic examination. (39)

Statement of Purpose

The aim of this project was to compare the recurrence rates of DFSP treated with surgical excision and Mohs surgery at Yale with the hypothesis that the recurrence rate of DFSP treated with surgical excision would be lower than the recurrence rate of DFSP treated with Mohs surgery.

Methods

Thirty patients were identified at the request of Drs. Aasi and Narayan by the Yale dermatopathology laboratory database as those who had been treated at this institution for DFSP from 1990, when the database was created, to 2005. Patients were divided into two treatment groups according to whether they had undergone surgical excision or Mohs surgery. Hospital and clinic charts were obtained by this author, who collect the following information: age at onset, sex, disease state (primary presentation versus recurrence), tumor site, preoperative and postoperative tumor size, excisional margin, duration of follow-up, and recurrence after treatment. Attempts were not made to contact patients when follow-up data was not available in their medical records.

The recurrence rate and average duration of follow-up were then calculated for each of the treatment groups by this author. Although data on excisional margins were available in the surgical excision group, data on excisional margins for the Mohs surgery group was not similarly available. Therefore, excisional margins were calculated in the following manner: the larger measurement of the preoperative tumor size was subtracted from the larger measurement of the postoperative defect size to obtain a total margin. This total margin was divided in half based on the assumption that the margin was applied circumferentially around the lesion to yield the actual margin. The smaller measurement of the preoperative tumor size was also subtracted from the smaller measurement of the postoperative defect size and divided in half. These two values were then averaged to arrive at the excisional margin for each patient.

Results

Patient characteristics

Of the 30 patients, 14 were in the surgical excision group, and 16 were in the Mohs surgery group. The age range in the surgical excision group was 10 to 84 years, and the mean age was 46 years \pm 19. The age range in the Mohs surgery group was 11 to 46 years, and the mean age was 38 years \pm 12. The distribution of sex was similar in each group; 71% , or 10 out of 14 patients, were female in the surgical excision group, and 69%, or 11 out of 16 patients, were female in the Mohs surgery group. While none of the 30 patients presented to Yale with local or distant metastasis, 3 patients presented with recurrent DFSP. Of these 3 patients, 1 was in the surgical excision group, and 2 were in the Mohs surgery group.

Tumor characteristics

In the surgical excision group, most of the DFSP lesions were on the trunk, and a fifth of them were on the head or neck. More specifically, there were 4 patients with lesions on the chest, 4 on the abdomen, and 3 on the back, totaling 11 out of 14 patients (79%) with lesions on the trunk. The remaining 3 out of 14 patients (21%) in the surgical excision group had lesions on the head or neck. (Figure 5) In the Mohs surgery group, approximately half of the DFSP lesions (56%) were on the trunk, and a quarter of the DFSP lesions were on the extremities. The remaining lesions were on the head or neck (2 out of 16 patients) and the vulva (1 out of 16 patients). More specifically, there were 4 patients with DFSP lesions on the chest, 3 on the abdomen, and 2 on the back, totaling 9

out of 16 patients with lesions on the trunk. Of the 4 DFSP lesions on the extremities in the Mohs surgery group, there were 3 lesions on the lower extremities and 1 lesion on the upper extremity. (Figure 6) The average area of the tumor was larger in the surgical excision group at $12.1 \text{ cm}^2 \pm 16.1$; the average area of the tumor in the Mohs surgery group was $5.3 \text{ cm}^2 \pm 5.9$.

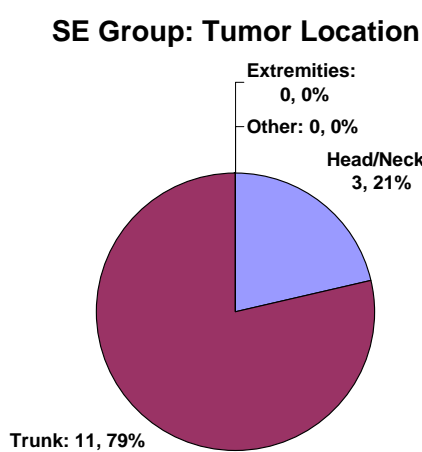


Figure 5: Distribution of tumor location in the surgical excision group, n=14.




Figure 6: Distribution of tumor location in the Mohs surgery group, n=16.

Surgical excision vs. Mohs surgery

Mohs surgery was performed on all 16 DFSP patients in the Mohs surgery group by 1 dermatologist in the Section of Dermatologic Surgery and Cutaneous Oncology in the Department of Dermatology at Yale. However, the 14 surgical excisions were carried out by 3 surgeons in the Section of Plastic Surgery in the Department of Surgery at Yale, as well as by the dermatologist previously mentioned. The three plastic surgeons operated on 3 patients, 3 patients, and 5 patients respectively, and the dermatologist

performed the remaining 2 surgical excisions.

The initial mean excisional margin for the surgical excision group was 2.8 cm \pm 0.4. However, 6 of the 14 patients in the surgical excision group had positive margins on the final pathology report from their initial surgery, and they underwent a second surgical excision by the same physician. (This second excision occurred within an average of 23 days \pm 13.) When the excisional margins from the revision surgery were added to the initial margins, the mean excisional margin for the surgical excision group became 3.8 cm \pm 1.6. (The width of the additional margins were available in the operative notes.) The mean excisional margin for the Mohs surgery group, however, was smaller at 1.4 cm \pm 0.5, and no revision procedures were required. The mean duration of follow-up in the surgical excision group was 33 months \pm 41, and the range of follow-up was 1 to 116 months. One of the patients in this group did not return for follow-up after her surgery. The mean duration of follow-up was shorter in the Mohs surgery group at 26 months \pm 25, and the range of follow-up was 2 to 69 months. Interestingly, one of the patients in this group did not return for follow-up after her surgery as well. (Table 3)

Table 3: Summary of treatment data

	Surgical Excision	Mohs Surgery
Margins	3.8 \pm 1.6 cm	1.4 \pm 0.5 cm
Follow-up	33 \pm 41 months	26 \pm 25 months
Recurrence	0/14, 0%	1/16, 6%

There was 1 recurrence in this series, and the patient was in the Mohs surgery group. This patient initially presented to Yale with a recurrent tumor, and he developed the recurrence 37 months after his Mohs surgery. The dermatologist removed the recurrent tumor with surgical excision. Therefore, the recurrence rate for the Mohs surgery group was 6% (1/16), and the recurrence rate for the surgical excision group was 0%.

Discussion

Dermatofibrosarcoma protuberans (DFSP) is a malignant soft tissue neoplasm with three key characteristics: it is very rare, it is slow growing, and it grows by asymmetric infiltration into deeper tissues. Although there is a consensus in the literature that tumor excision is the most effective treatment of DFSP, there is currently no consensus on which excisional technique is the most effective, because the microscopic finger-like projections of DFSP are difficult to eradicate completely in either wide surgical excision or Mohs micrographic surgery. Recurrence rates vary widely for both procedures, and moreover, recommended resection margins vary widely for wide surgical excisions.

Since the first studies in 1951, the literature currently contains over 30 series in which DFSP was removed by surgical excision. (Table 4) The average recurrence rate was 23% (range: 0% to 60%), and the total recurrence rate was 21% (334/1598). Given the variable follow-up periods, which ranged from 1 month to 25 years when stated, as well as variable numbers of patients, which ranged from 7 to 218, the large range of

recurrence rates is not surprising. Resection margins also ranged from “conservative” to 5 cm when they were defined, but the vast majority of studies used excisional margins greater than or equal to 2 cm. However, tumor location can limit the width of margins in surgical excision; generous excisional margins are not practical for DFSP on the face or distal extremities. (38)

Table 4: Local recurrence rates after surgical excision of DFSP

Authors	Year	N, patients	N, recurrences	Recurrence rate, %	Follow-up, yrs
Pack, Tabah (5)	1951	39	8	21	0.5-20
Gentele (43)	1951	38	16	42	NS
McGregor (44)	1961	7	0	0	1-6
Taylor, Helwig (17)	1962	98	48	49	1-17
Burkhardt, et al. (12)	1966	21	7	33	>5
McPeak, et al. (6)	1967	82	8	10	3-15
Longhin (45)	1967	44	14	32	1-11
Tamoney (46)	1971	12	3	25	1-30
Hadju (47)	1979	119	64	53	NS
Bendix-Hansen, et al. (7)	1983	18	8	44	5-13
Barnes, et al. (48)	1984	15	8	53	1-23
Waldermann, Hagedorn (49)	1985	13	3	23	1-7
Petoin, et al. (50)	1985	96	6	6	1-15
Roses, et al. (40)	1986	48	16	33	>3
Chattopadhyay, et al. (51)	1986	10	6	60	5-7
Rutgers, et al. (14)	1992	19	8	42	2-28
Brabant, et al. (52)	1993	14	0	0	1-5
Mark, et al. (53)	1993	15	9	60	3-16
Koh, et al. (54)	1995	19	5	26	>3
Gloster, et al. (38)	1996	39	5	13	0.8-14
Arnaud, et al. (55)	1997	107	2	2	NS
Gayner, et a. (56)	1997	32	11	34	0.8-24
Sondak, et al. (57)	1999	45	0	0	NS
Lindner, et al. (37)	1999	35	20	37	1-12
Stojadinovic, et al. (58)	2000	33	3	9	NS
Bowne, et al. (15)	2000	159	34	21	NS
D'Andrea, et al. (59)	2001	14	1	7	2-8
Oliveira-Soares, et al. (60)	2001	13	2	15	0.16-17
Vandeweyer, et al. (61)	2002	18	1	5.5	NS
Khatri, et al. (9)	2003	24	0	0	NS
Chang, et al. (8)	2004	60	10	17	1-25
Dubay, et al. (62)	2004	40	0	0	NS
Fiore, et al. (63)	2005	218	8	4	NS
Behbahani (64)	2005	34	0	0	NS
Totals		1598	334	21	

The use of Mohs surgery in the treatment of DFSP was first described in 1978 by

Mohs himself. (65) The literature currently contains at least 27 reports in which DFSP was removed by Mohs surgery, but almost a third of these reports have only 1 or 2 patients in them. (Table 5) The average recurrence rate was 1.9% (range: 0% to 14%), and the total recurrence rate was 2.7% (9/337). Therefore, recurrence rates for Mohs surgery are lower than recurrence rates for surgical excision. However, patients with surgical excision had a longer follow-up period, so patients with Mohs surgery may have late recurrences. Also, Mohs surgery has several drawbacks that limit its widespread use in the treatment of DFSP. (57) The Mohs surgeon requires considerable training, as well as a specialized ancillary team, and the learning curve is steep. (57) Moreover, the surgery itself is labor and time intensive, and since it is performed under local anesthesia, large or bulky tumors are difficult to remove. (57)

Table 5: Local recurrence rates after Mohs surgery for DFSP

Authors	Year	N, patients	N, recurrences	Recurrence rate, %	Follow-up, months
Mohs (65)	1978	7	0	0	>60
Mikhail, Lynn (66)	1978	2	0	0	>60
Peters, et al. (67)	1982	1	0	0	42
Hess, et al. (68)	1985	1	0	0	18
Robinson (69)	1985	4	0	0	>60
Hobbs, Ratz (70)	1988	1	0	0	25
Hobbs, et al. (71)	1988	10	0	0	15-91
Weber, et al. (72)	1988	1	0	0	6
Rockley, et al. (73)	1989	1	0	0	18
Goldberg, Maso (74)	1990	1	0	0	12
Parker, Zitelli (75)	1995	20	0	0	3-105
Dawes, Hanke (76)	1996	24	2	8	NS
Gloster, et al. (38)	1996	15	1	7	5-96
Barlow, et al. (77)	1996	2	0	0	24-35
Kelley, et al. (78)	1996	21	3	14	>60
Garcia, et al. (79)	1996	16	0	0	NS
Ratner, et al. (80)	1997	58	1	2	3-170
Haycox, et al. (81)	1997	10	0	0	NS
Hafner, et al. (82)	1999	5	0	0	NS
Huether, et al. (83)	2000	18	1	5.5	NS
Ah-Weng, et al. (84)	2002	21	0	0	21-80
Nouri, et al. (85)	2002	20	0	0	4-216

Oliveira-Soares, et al. (60)	2002	7	1	14	NS
Tom, et al. (86)	2003	9	0	0	19-74
Wacker, et al. (87)	2004	22	0	0	NS
DuBay, et al. (62)	2004	11	0	0	NS
Snow, et al. (42)	2004	29	0	0	60-240
Totals		337	9	2.7	

In this study, there was no recurrence in the surgical excision group, and there was 1 recurrence in the Mohs surgery group, resulting in a 6% recurrence rate for Mohs surgery and supporting the hypothesis that the recurrence rate of DFSP treated with surgical excision would be lower than the recurrence rate of DFSP treated with Mohs surgery. However, this conclusion must be considered in light of several key limitations to this study.

First, this study had a small n since DFSP is a very rare disease; there were 14 patients in the surgical excision group and 16 patients in the Mohs surgery group. Therefore, 1 or 2 recurrences can completely change the results of the study. Even 1 recurrence in the surgical excision group would lead to a 7% recurrence rate, and the rate of recurrence in the surgical excision group would be higher than the rate of recurrence in the Mohs surgery group.

Second, all of the patients in the study were referred to the dermatologist or plastic surgeon by their primary care physicians, but they were not randomly assigned to the 2 treatment groups. However, the patients were not assigned to the 2 treatment groups by any identifiable criteria either. Therefore, one cannot completely compare treatment outcomes, such as the recurrence rate, to conclude that one treatment modality is more effective than the other is.

Third, even if all of the patients were randomly assigned to the 2 treatment groups, comparing recurrence rates to evaluate the efficacy of surgical excision and Mohs surgery

also depends on the length of follow-up. More specifically, only recurrence rates at the same time point can be meaningfully compared, and the latest time point at which recurrence rates can be compared is equal to the shortest duration of follow-up among all of the patients. In this study, the shortest duration of follow-up was only 1 month, despite a mean duration of follow-up for all of the patients of 29 months, and there were no recurrences in both the surgical excision and Mohs surgery groups at 1 month. However, no other meaningful comparisons of recurrence rates can be made beyond this time frame.

Finally, comparing recurrence rates for surgical excision and Mohs surgery demands adjustment for key factors, such as patient and tumor characteristics, in a multivariate analysis, because increased age, histologic subtype, high mitotic index, cellularity, location on the head and neck, and recurrent lesions are associated with higher recurrence rates. (15, 53, 56, 88) Most recurrences occur within 3 years of the primary excision, and recurrent tumors tend to recur. (6, 17, 40, 48, 53) Investigators in Germany specifically measured the subclinical spread of DFSP and found that, on average, recurring tumors infiltrated twice as far beyond the clinically visible tumor margin (22.4 mm) as primary tumors (10.0 mm). (89)

There are 2 ways to overcome these limitations in order to compare the outcomes of surgical excision and Mohs surgery in the treatment of DFSP. To increase the size of the study, concurrent data could be pooled from other institutions, or this data could be added to previous series listed in Tables 4 and 5, to make meaningful statistical analysis

possible. Moreover, this study would benefit greatly from contacting patients lost to follow-up in order to compare recurrence rates of surgical excision and Mohs surgery beyond 1 month.

However, while tumor resection remains the mainstay of treatment of DFSP, radiation therapy (RT) has an adjuvant role. Although data assessing the efficacy of RT alone in the treatment of macroscopic disease is currently limited, several studies have concluded that RT administered before either before or after surgery significantly reduces the risk of local recurrence in patients who have or who are likely to have close or positive margins when wide excision would result in cosmetic or functional loss. (90, 91, 92, 93) In the most recent study in this series, 1 of the 10 patients (10%) who received adjuvant RT after surgical resection developed a recurrence, and 9 of the 24 patients (37.5%) who received only surgical resection developed a recurrence. (94) The appropriate dose fractionation schedules and treatment techniques are similar to those that are used for other soft tissue sarcomas. (95) Moreover, after reviewing a series of studies evaluating the efficacy of RT, the authors conclude that despite the limited data, RT alone is reasonably likely to result in cure for the occasional patient with unresectable macroscopic disease. (96) However, the slow growth rate of DFSP precludes the use of chemotherapy as an effective treatment modality, (10) but may be used in metastatic disease. (49)

Finally, an additional adjuvant treatment option may be molecularly targeted therapy against the fusion protein COL1A1-PDGFB. As discussed above, this molecule

is found in DFSP tumors and stimulates tumor growth. Although originally approved for the treatment of chronic myelogenous leukemia, imatinib/STI-571 (Gleevec), which is a potent and specific inhibitor of several protein-tyrosine kinases, also interrupts the continuous stimulation of the DFSP cells by inhibiting platelet-derived growth factor receptors in vitro (34, 97) and in selected patients. (98) In 2003, the Task Force for Dermatologic Oncology (ADO), together with the German Society for Dermatologic Surgery and Oncology, initiated an open, multi-institutional phase II study to evaluate the therapeutic efficacy of Gleevec in a larger patient population. (11)

References

1. Taylor RW. Sarcomatous tumors resembling in some respects keloid. *J Cutan Genitourin Dis.* 1890;8:384.
2. Darier J, Ferrand M. Dermatofibromes progressifs et recidivants ou fibrosarcomes de la peau. *Ann Dermat et Syph.* 1924;5:545.
3. Hoffmann E. Uber das knollentreibende firbosarkon der haut (dermatofibrosarkoma protuberans). *Dermat Ztschr.* 1925;43:1.
4. Enzinger FM, Weiss SW. *Soft tissue tumors*, ed 2. St. Louis, Mosby-Year Book, 1988; 1.
5. Pack GT, Tabah EJ. Dermatofibrosarcoma protuberans: a report of 39 cases. *Arch Surg.* 1951;62:391-411.
6. McPeak CJ, Cruz T, Nicastrì AD. Dermatofibrosarcoma protuberans: an analysis of 86 cases—five with metastasis. *Ann Surg.* 1967;166:803-16.
7. Bendix-Hansen K, Myhre-Jensen O, Kaae S. Dermatofibrosarcoma protuberans: a clinicopathological study of 19 cases and review of the world literature. *Scand J Plas Reconstr Surg.* 1983;17:247-52.
8. Chang CK, Jacobs IA, Salti GI. Outcomes of surgery for dermatofibrosarcoma protuberans. *Eur J Surg Oncol.* 2004;30:341-5..
9. Khatri VP, Galante JM, Bold RJ, Schneider PD, Ramsamooj R, et al. Dermatofibrosarcoma protuberans: reappraisal of wide local excision and impact of inadequate treatment. *Ann Surg Oncol.* 2003;10(9):1118-22.
10. Laskin WB. Dermatofibrosarcoma protuberans. *CA: A Cancer J for Clinicians.* 1992;42:116-25.
11. Breuninger H, Sebastian G, Garbe C. Dermatofibrosarcoma protuberans—an update. *J der Deutschen Dermatologischen Gesellschaft.* 2004;2:661-7.
12. Burkhardt BR, Soule EH, Winkelmann RK, Ivins JC. Dermatofibrosarcoma protuberans: study of fifty-six cases. *Am J Surg.* 1966;111:638-44.
13. Manalan SS, Cohen IK, Theogaraj SD. Dermatofibrosarcoma protuberans or keloid: a warning. *Plast Reconstruc Surg.* 1974;54:96-8.
14. Rutgers EJ, Kroon BB, Albus-Lutter CE, Gortzak E. Dermatofibrosarcoma protuberans: treatment and prognosis. *Eur J Surg Oncol.* 1992;18:241-8.

15. Bowne WB, Antonescu CR, Leung DH, Katz SC, Hawkins, WG. Dermatofibrosarcoma protuberans: a clinicopathologic analysis of patients treated and followed at a single institution. *Cancer*. 2000;88:2711-20.
16. Weber PJ, Gretzula JC, Hevia O. Dermatofibrosarcoma protuberans. *J Dermatol Surg Oncol*. 1988;14:555-8.
17. Taylor HB, Helwig EB. Dermatofibrosarcoma protuberans: a study of 115 cases. *Cancer*. 1962;15:717.
18. Fletcher CDM, Evans BJ, MacArtney JC. Dermatofibrosarcoma protuberans: a clinicopathological and immunohistochemical study with a review of the literature. *Histopathol*. 1985;9:921-38.
19. Brenner W, Schaefer K, Chhabra H, Postel A. Dermatofibrosarcoma protuberans metastatic to a regional lymph node: report of a case and review. *Cancer*. 1975;36:1897-1902.
20. Civin CI, Strauss LC, Brovall C, Fackler MJ, Schwartz JF, et al. A hematopoietic progenitor cell surface antigen defined by a monoclonal antibody raised against KG-1a cells. *J Immunol*. 1984;133:157-65.
21. Fina L, Molgaard HB, Robertson D. Expression of the CD34 gene in vascular endothelial cells. *Blood*. 1990;75:2417-26.
22. Traweek ST, Kandalaf PL, Mehta P, Battifora H. The human hematopoietic progenitor cell antigen (CD34) in vascular neoplasia. *Am J Surg Pathol*. 1991;96:25-31.
23. Nickoloff BJ. The human progenitor cell antigen (CD34) is localized on endothelial cells, dermal dendritic cells, and perifollicular cells in formalin-fixed normal skin, and on proliferating endothelial cells and stromal spindle-shaped cells in Kaposi's sarcoma. *Arch Dermatol*. 1991;127:523-9.
24. Cerio R, Griffiths CEM, Cooper KD, Nickoloff BJ, Headington JT. Characterization of factor XIIIa positive dermal dendrocytes in normal and inflamed skin. *Br J Dermatol*. 1989;121:421-32.
25. McDonagh J. Structure and function of factor XIIIa. In: Coleman RW, Hirsh J, Marder VJ, Salzman EW, eds. *Hemostasis and thrombosis: basic principles and clinical practice*. Philadelphia:JB Lippincott. 1982:289-300.
26. Abenoza P, Lillemoe T. CD34 and factor XIIIa in the differential diagnosis of dermatofibroma and dermatofibrosarcoma protuberans. *Am J Dermatopathol*. 1993;15:429-434.
27. Calikoglu E, Augsburger E, Chavez P, Saurat JH, Kaya G. CD44 and hyaluronate in

the differential diagnosis of dermatofibroma protuberans. *J Cutan Pathol.* 2003;30:185-189.

28. Fanburg-Smith JC, Miettinen M. Low-affinity nerve growth factor receptor (p75) in dermatofibrosarcoma protuberans and other nonneural tumors: a study of 1,150 tumors and fetal and adult normal tissues. *Hum Pathol.* 2001;32:976-83.

29. West RB, Harvell J, Linn SC, Lui CL, Prapong W, et al. Apo D in soft tissue tumors: a novel marker for dermatofibrosarcoma protuberans. *Am J Surg Oncol.* 2004;28:1063-9.

30. Elgart GW, Hanly A, Busso M, Spencer JM. Bednar tumor (pigmented dermatofibrosarcoma protuberans) occurring in a site of prior immunization: immunochemical findings and therapy. *J Am Acad Dermatol.* 1999;40(2Pt 2):315-7.

31. Nishio J, Iwasaki H, Ohjimi Y, Ishiguro M, Isayama T, Naito M, Iwashita A, Kikuchi M. Overrepresentation of 17q22-qter and 22q13 in dermatofibrosarcoma protuberans but not in dermatofibroma: a comparative genomic hybridization study. *Cancer Genet Cytogenet.* 2002;132:102-108.

32. O'Brien KP, Seroussi E, Dal Cin P, Sciort R, Mandahl N, et al. Various regions within the alpha-helical domain of the COL1A1 gene are fused to the second exon of the PDGFβ gene in dermatofibrosarcomas and giant-cell fibromas. *Genes Chromosomes Cancer.* 1998;23:187-93.

33. Simon MP, Navarro M, Roux D, Pouyssegur J. Structural and functional analysis of a chimeric protein COL1A1-PDGFβ generated by the translocation t (17;22) (q22;q13.1) in dermatofibrosarcoma protuberans (DP). *Oncogene.* 2001;20:2965-75.

34. Sjoblom T, Shimizu A, O'Brien KP. Growth inhibition of dermatofibrosarcoma protuberans tumors by the platelet-derived growth factor receptor antagonist STI571 through induction of apoptosis. *Cancer Res.* 2001;61:5778-83.

35. Torreggiani WC, Al-Ismael K, Munk PL, Nicolau S, O'Connell JX, et al. Dermatofibrosarcoma protuberans: MR imaging features. *Am J Roentgenol.* 2002;178:989-93.

36. [No authors listed]. Soft tissue sarcoma. In: Greene PL, Page DL, Fleming ID, eds. *AJCC cancer staging manual* (6th edition). New York: Springer-Verlag. 2002;193-200.

37. Lindner NJ, Scarborough MT, Powel GJ, Spanier S, Enneking WF. Revision surgery in dermatofibrosarcoma protuberans of the trunk and extremities. *Eur J Surg Oncol.* 1999;25:392-7.

38. Gloster HM, Harris KR, Roenigk RK. A comparison between Mohs micrographic surgery and wide surgical excision for the treatment of dermatofibrosarcoma protuberans.

J Am Academy Dermatol. 1996;35:82-7.

39. Mooney M, Parry E. Mohs micrographic surgery. From emedicine webpage. 2005. <http://www.emedicine.com/derm/topic542.htm>

40. Roses DF, Valensi Q, LaTrenta G, Harris MN. Surgical treatment of dermatofibrosarcoma protuberans. Surg Gynecol Obstetrics. 1986;162:449-52.

41. Mohs FE. Origin and progress of Mohs micrographic surgery. In: Mikhail GR, ed. Mohs micrographic surgery. Philadelphia. WB Saunders Co; 1991:1-10.

42. Snow SN, Gordon EM, Larson PO, Bagheri MM, Bentz ML, et al. Dermatofibrosarcoma protuberans: a report on 29 patients treated by Mohs micrographic surgery with long-term follow-up and review of the literature. Cancer. 2004;101:28-38.

43. Gentile H. Malignant, fibroblastic tumors of the skin: clinical and pathological-anatomical studies of 129 cases of malignant, fibroblastic tumors from cutaneous and subcutaneous layers observed at Radiumhemmet during period 1927-1947. Acta Derm Venereol Suppl. 1951;27:1-180.

44. McGregor JK. Role of surgery in the management of dermatofibrosarcoma protuberans. Ann Surg. 1961;154:255-8.

45. Longhin S. Considerations on the histopathologic diagnosis and treatment of the Darier-Ferrand dermatofibroma. Ann Dermatol Syphiligr. 1967;94:158-68.

46. Tamoney HJ. Dermatofibrosarcoma protuberans: a review of 12 cases. Conn Med. 1971;35:674-80.

47. Hadju SI. Pathology of soft tissue tumors. Philadelphia: Lea & Febiger. 1979;82-94.

48. Barnes L, Coleman JA, Johnson JT. Dermatofibrosarcoma protuberans of the head and neck. Arch Otolaryngol. 1984;110:398-404.

49. Waldermann F, Hagedorn M. Clinical picture and pathology of dermatofibrosarcoma protuberans. Z Hautkr. 1985;60:1886-8, 1891-4.

50. Petoian DS, Verola O, Banzet P. Darier-Ferrand dermatofibrosarcoma: study of 96 cases over 15 years. Chirurgie. 1985;111:132-8.

51. Chattopadhyay TK, Sing MK, Aruna BH. Dermatofibrosarcoma protuberans: a clinicopathological study of 10 cases. Jpn J Surg. 1986;16:435-8.

52. Brabant B, Revol M, Vergote T. Dermatofibrosarcoma protuberans of the chest and shoulder: wide and deep excisions with immediate reconstruction. Plast Reconstr Surg. 1993;92:459-62.

53. Mark RJ, Bailet JW, Tran LM. Dermatofibrosarcoma protuberans of the hand and neck: a report of 16 cases. *Arch Otolaryngol Head Neck Surg.* 1993;119:891-6.
54. Koh CK, Ho CB, Bury HPR. Dermatofibrosarcoma protuberans. *Int J Dermatol.* 1995;34:256-60.
55. Arnaud EJ, Perrault M, Revol M, Servant JM, Banzet P. Surgical treatment of dermatofibrosarcoma protuberans. *Plast Reconstr Surg.* 1997;100:884-95.
56. Gayner SM, Lewis JE, McCaffrey TV. Effect of resection margins on dermatofibrosarcoma protuberans of the head and neck. *Arch Otolaryngol Head Neck Surg.* 1997;123:430-3.
57. Sondak VK, Cimmino VM, Lowe LM, DuBay DA, Johnson TM. Dermatofibrosarcoma protuberans: what is the best surgical approach? *Surg Oncol.* 1999;8:183-9.
58. Stojadinovic A, Karpoff HM, Antonescu CR, Shah JP, Singh B, et al.. Dermatofibrosarcoma protuberans of the head and neck. *Ann Surg Oncol.* 2000;7:696-704.
59. D'Andrea F, Vozza A, Brongo S, Girolamo FD, Vozza G. Dermatofibrosarcoma protuberans: experience with 14 cases. *Eur Acad Dermatol Vereol.* 2001;15:427-9.
60. Oliveira-Soares R, Viana I, Vale E, Soares-Almeida LM, Picoto A. Dermatofibrosarcoma protuberans: a clinicopathological study of 20 cases. *Eur Acad Dermatol Venereol.* 2002;16:441-6.
61. Vandeweyer E, De Saint Aubain Somerhausen N, Gebhart M. Dermatofibrosarcoma protuberans: how wide is wide in surgical excision? *Acta Chirurgicalia Belgica.* 2002;102:455-8.
62. DuBay D, Cimmino V, Lowe L, Johnson TM, Sondak VK. Low recurrence rate after surgery for dermatofibrosarcoma protuberans: a multidisciplinary approach from a single institution. *Cancer.* 2004;100:1008-16.
63. Fiore M, Miceli R, Mussi C, Lo Vullo S, et al. Dermatofibrosarcoma protuberans treated at a single institution: a surgical disease with a high cure rate. *J Clin Oncol.* 2005;23:7669-75.
64. Behbahani R, Patenotre P, Capon N, Martinot-Dequennoy V, Kulik JF, et al. To a margin reduction in the dermatofibrosarcoma protuberans? A retrospective study of 34 cases. *Ann Chirurgie Plastique Esthetique.* 2005;50:179-85, 186-8.
65. Mohs FE. Chemosurgery: microscopically controlled surgery for skin cancer.

Springfield, IL: Charles C Thomas. 1978:251.

66. Mikhail GR, Lynn BH. Dermatofibrosarcoma protuberans. *J Dermatol Surg Oncol.* 1978;4:81-4.
67. Peters CW, Hanke CW, Pasarell HA, Bennett JE. Chemosurgical reports: Dermatofibrosarcoma protuberans of the face. *J Dermatol Surg Oncol.* 1982;8:823-6.
68. Hess KA, Hanke CW, Estes NC. Chemosurgical reports: myxoid Dermatofibrosarcoma protuberans. *J Dermatol Surg Oncol.* 1982;11:268-71.
69. Robinson JK. Dermatofibrosarcoma protuberans resected by Mohs surgery (chemosurgery): a 5-year prospective study. *J Am Acad Dermatol.* 1985;12:1093-8.
70. Hobbs ER, Ratz JL. Dermatofibrosarcoma protuberans of the hand: report of a case treated with Mohs micrographic surgery. *Cleve Clin J Med.* 1988;55:252-6.
71. Hobbs ER, Wheeland RG, Bailin PL. Treatment of Dermatofibrosarcoma protuberans with Mohs micrographic surgery. *Ann Surg.* 1988;207:102-7.
72. Weber PJ, Gretzula JC, Hevia O. Dermatofibrosarcoma protuberans. *J Dermatol Surg Oncol.* 1988;14:555-8.
73. Rockley PF, Robinson JK, Magid M. Dermatofibrosarcoma protuberans of the scalp: a series of cases. *J Am Acad Dermatol.* 1989;21:278-83.
74. Goldberg DJ, Maso M. Dermatofibrosarcoma protuberans in a 9-year old child: treatment by Mohs micrographic surgery. *Pediatr Dermatol.* 1990;7:57-9.
75. Parker TL, Zitelli JA. Surgical margins for excision of Dermatofibrosarcoma protuberans. *J Am Acad Dermatol.* 1995;32:233-6.
76. Dawes KW, Hanke CW. Dermatofibrosarcoma protuberans treated with Mohs micrographic surgery: cure rates and surgical margins. 1996;22:530-4.
77. Barlow RJ, Ramnarain N, Smith N, Mayou B, Markey AC, et al. Excision of selected skin tumours using Mohs micrographic surgery with horizontal paraffin-embedded sections. *Brit J Dermatol.* 1996;135:911-7.
78. Kelley I, Dudley C, Snow SN, Hruza GJ. Treatment of Dermatofibrosarcoma protuberans with Mohs micrographic surgery: a review of 50 cases. 28th Annual Meeting Am College Mohs Micrographic Surgery and Cutaneous Oncology (ACMMSO), Palm Desert, CA, 1996.
79. Garcia C, Clark RE, Buchanan M. Dermatofibrosarcoma protuberans. *Int J Dermatol.* 1996;35:867-71.

80. Ratner D, Thomas CO, Johnson TM, Sondak VK, Hamilton TA, et al. Mohs micrographic surgery for the treatment of Dermatofibrosarcoma protuberans. Results of a multiinstitutional series with an analysis of the extent of microscopic spread. *J Am Acad Dermatol.* 1997;37:600-13.
81. Haycox CL, Odland PB, Olbricht SM, Casey B. Dermatofibrosarcoma protuberans: growth characteristics based on tumor remodeling and a review of cases treated with Mohs micrographic surgery. *Ann Plast Surg.* 1997;38:246-51.
82. Hafner J, Schutz K, Morgenthaler W, Steiger E, Meyer V, et al. Micrographic surgery (slow Mohs) in cutaneous sarcomas. *Derm.* 1999;198:37-43.
83. Huether MJ, Zitelli JA, Brodland DG. Mohs micrographic surgery for the treatment of spindle cell tumors of the skin. *J Am Acad Dermatol.* 2001;44:656-9.
84. Ah-Weng, Marsden JR, Sanders DSA, Waters R. Dermatofibrosarcoma protuberans treated by Mohs micrographic surgery. *Brit J Cancer.* 2002;87:1386-9.
85. Nouri K, Lodha R, Jimenez G, Robins P. Mohs micrographic surgery for Dermatofibrosarcoma protuberans: University of Miami and NYU experience. *Dermatol Surg.* 2002;28:1060-4.
86. Tom WD, Hybarger CP, Rasgon BM. Dermatofibrosarcoma protuberans of the head and neck: treatment with Mohs surgery using inverted horizontal paraffin sections. *Laryngoscope.* 2003;113:1289-93.
87. Wacker J, Khan-Durani B, Hartschuh W. Modified Mohs micrographic surgery in the therapy of Dermatofibrosarcoma protuberans: analysis of 22 patients. *Ann Surg Oncol.* 2004;11:438-44.
88. Mentzel T, Beham A, Katenkamp D, Dei Tos A, Fletcher C. Fibrosarcomatous ("high grade") dermatofibrosarcoma protuberans: clinicopathologic and immunohistochemical study of a series of 41 cases with an emphasis on prognostic significance. *Am J Surg Path.* 1998;22:576-87.
89. Breuninger H, Thaller A, Schippert W. Subclinical spread of dermatofibrosarcoma protuberans and resulting treatment modalities. *Hautarzt.* 1994;45:541-5.
90. Ballo MT, Zagars GK, Pisters P, Pollack A. The role of radiation therapy in the management of dermatofibrosarcoma protuberans. *Int J Radiat Oncol Biol Phys.* 1998;40:823-827.
91. Haas RL, Keus RB, Loftus BM, Rutgers EJ, van Coevorden F, et al. The role of radiotherapy in the local management of dermatofibrosarcoma protuberans. *Soft Tissue Tumors Working Group. Eur J Cancer.* 1997;33:1055-1060.

92. Suit H, Spiro I, Mankin HJ, Efird J, Rosenberg AE. Radiation in management of patients with dermatofibrosarcoma protuberans. *J Clin Oncol.* 1996;14:2365-2369.
93. Marks LB, Suit HD, Rosenberg AE. Dermatofibrosarcoma protuberans: treatment and prognosis. *Eur J Surg Oncol.* 1992;18:1093-8.
94. Sun LM, Chong JW, Huang C, Leung SW, Chen HC, et al. Dermatofibrosarcoma protuberans: treatment results of 35 cases. *Radiotherapy Oncol.* 2000;57:175-181.
95. Parsons JT, Ziotecki RA, Reddy KA, Mitchell TP, Marcus RB, et al. The role of radiotherapy and limb-conserving surgery in the management of soft-tissue sarcomas in adults. *Hematol Oncol Clin North Am.* 2001;15:377-388.
96. Mendenhall WM, Ziotecki RA, Scarborough MT. Dermatofibrosarcoma protuberans. *Cancer.* 2004;101:2503-8.
97. Sirvent N, Maire G, Pedoutour F. Genetics of dermatofibrosarcoma protuberans family of tumors: From ring chromosomes to tyrosine kinase inhibitor treatment. *Genes Chromosomes Cancer.* 2003;37:1-19.
98. Maki RG, Awan RA, Dixon RH, Jhanwar S, Antonescu CR. Differential sensitivity to imatinib of 2 patients with metastatic sarcoma arising from dermatofibrosarcoma protuberans. *Int J Cancer.* 2002;100:623-626.