

Yale University

## EliScholar – A Digital Platform for Scholarly Publishing at Yale

---

Yale Medicine Thesis Digital Library

School of Medicine

---

11-15-2006

# Uterine Arterial Embolization: Classification of Leiomyomas to Determine Predictors of Response

Trusher Patel

Follow this and additional works at: <http://elischolar.library.yale.edu/ymtdl>

---

### Recommended Citation

Patel, Trusher, "Uterine Arterial Embolization: Classification of Leiomyomas to Determine Predictors of Response" (2006). *Yale Medicine Thesis Digital Library*. 278.

<http://elischolar.library.yale.edu/ymtdl/278>

This Open Access Thesis is brought to you for free and open access by the School of Medicine at EliScholar – A Digital Platform for Scholarly Publishing at Yale. It has been accepted for inclusion in Yale Medicine Thesis Digital Library by an authorized administrator of EliScholar – A Digital Platform for Scholarly Publishing at Yale. For more information, please contact [elischolar@yale.edu](mailto:elischolar@yale.edu).

*Uterine Arterial Embolization: Classification of  
Leiomyomas to Determine Predictors of Response*

A Thesis Submitted to the  
Yale University School of Medicine  
in Partial Fulfillment of the Requirements for the  
Degree of Doctor of Medicine

By

**Trushar Patel**

2006

**Abstract***Uterine Arterial Embolization: Classification of Leiomyomas to Determine Predictors of Response*

Trushar J. Patel, Sharon D'Heureux, and Michael J. Tal. Section of Interventional Radiology, Department of Diagnostic Radiology, Yale University, School of Medicine, New Haven, CT

The purpose of this study is to determine features of uterine leiomyoma on Magnetic Resonance Imaging (MRI) that identify predictors of response to Uterine Arterial Embolization (UAE). MRI images were obtained before and after UAE in 35 women. These images were analyzed for uterine and fibroid size changes along with fibroid border characteristics and location for a total of 73 fibroids. Fibroids were classified as either smooth or lobulated based on border appearance on MR imaging to determine any differences in mean fibroid volume reduction post-embolization. The mean decrease in fibroid volume from pre-embolization to post-embolization was  $48.1\% \pm 28.6\%$  (SD) ( $P < 0.001$ ). No statistical difference was detected in the mean volume reduction between lobulated and smooth fibroids,  $40.6\% \pm 23.1\%$  (SD) and  $50.9\% \pm 30.2\%$  (SD) respectively, with a confidence interval [-25.1, 4.6, SEM 7.5, Df 71], single factor ANOVA ( $F[1,71]=1.88$ ,  $F_{crit}=3.98$ ,  $p=0.17$ ). However, some difference was detected in the failure rate of lobulated versus smooth fibroids to embolization, 5% and 9.4% respectively, ANOVA ( $F [1, 71]= 0.37$ ,  $F_{crit}= 3.98$ ,  $p > 0.1$ ), albeit at low statistical power. Also no difference was detected in mean fibroid volume reduction between intramural, submucosal, and subserosal fibroids. Thus, we introduced a novel characteristic by which to classify uterine fibroids based upon border appearance on MR imaging.

## Acknowledgement

I would like to thank:

- Michael Tal – Thank you for your support as my advisor and mentor through all of the work and writing that went into this project. Overall your guidance has been instrumental in not only this work, but throughout my third and fourth years in medical school.
- Sharon D'Heureux – I appreciate all of the effort and work you did that went into this project. Thank you for your assistance and help with the imaging parameters.
- Jorge Galvez – Thank you for the creation of the initial database that gave us such a wealth of information.
- My family – To Jayanti and Bhavana Patel and my brother Tejas, thank you for all of your support and help, without which I would be lost.

## TABLE OF CONTENTS

Abstract .....	ii
Acknowledgement .....	iii
<b>Table of Contents.....</b>	<b>iv</b>
<b>CHAPTER 1 .....</b>	<b>1</b>
<b>Introduction.....</b>	<b>1</b>
Background / Incidence .....	1
Risk Factors .....	1
Clinical Presentation.....	2
Medical Management .....	3
Surgical Management.....	4
Hysterectomy .....	4
Myomectomy .....	5
Hysteroscopic Myomectomy .....	5
Laparoscopic Uterine Artery Occlusion .....	6
Uterine Artery Embolization.....	6
Indication for Embolization .....	6
Technique of Embolization .....	8
Results of Embolization .....	9
Pregnancy after UFE .....	9
Complications of Embolization.....	10
<b>CHAPTER 2 .....</b>	<b>13</b>
<b>Statement of Purpose.....</b>	<b>13</b>
<b>CHAPTER 3 .....</b>	<b>15</b>
<b>Materials and Methods .....</b>	<b>15</b>
Embolization.....	15
Image Evaluation.....	15
Data Analysis.....	18
Contribution.....	18
<b>CHAPTER 4 .....</b>	<b>20</b>
<b>Results .....</b>	<b>20</b>
Volume Changes.....	20
Prognostic Features.....	20

<b>CHAPTER 5 .....</b>	<b>25</b>
<b>Discussion.....</b>	<b>25</b>
Discussion .....	25
Uterine volumes.....	25
Fibroid volumes.....	26
Predictive Factors .....	27
Limitations of the study.....	28
Conclusion .....	30
<b>CHAPTER 6 .....</b>	<b>32</b>
<b>Bibliography .....</b>	<b>32</b>

## *Chapter 1*

### INTRODUCTION

#### **Background / Incidence**

Uterine leiomyomas, also known as fibroids, are benign tumors arising from the smooth muscle of the uterus and contain various amounts of interstitial fibrotic tissue. Although the genesis of such fibroids is uncertain, it is thought that a multi-factorial process involving hormone dysregulation along with genetic factors may play a large role in the formation of uterine fibroids. Gonadal steroids are thought to play a large role in the growth of fibroids, however the formation of fibroids is not necessarily linked to these hormones.

While the true incidence of fibroids is unknown due to the high prevalence of asymptomatic patients, the reported incidence is generally between 20% and 40% with a much higher incidence of nearly 50% in women of African-American heritage. In African American women, the estimated cumulative incidence by age 50 is greater than 80%, while in Caucasian women the estimated cumulative incidence by age 50 is around 70% (1). Most women with symptomatic fibroids are between 30 and 40, with few fibroids described in adolescent women.

#### **Risk Factors**

Women of African American descent are two to three times as likely to develop fibroids as Caucasian women. In addition to increased incidence, African American women are likely to be younger at the time of presentation with greater severity of disease related to higher uterine volumes and increased bleeding (2). Other risk factors for fibroid formation include

nuliparity (3, 4) and family history of fibroids (5). Factors that have been shown to reduce risk for fibroid formation include parity, and smoking, through an unknown mechanism (3).

### **Clinical Presentation**

As mentioned previously, a large number of women with uterine fibroids are asymptomatic. Fibroids that are symptomatic can manifest with a variety of symptoms. While the clinical presentation of fibroids differs in each woman, the most common presenting symptom is that of menorrhagia or metrorrhagia. Symptoms are typically related to the size, location, and direction of growth of the fibroids, and fall into three broad categories, uterine bleeding, pelvic pressure, and disturbances in reproduction. As mentioned uterine bleeding is typically menorrhagia or metrorrhagia and can result in other secondary symptoms related to anemia, such as fatigue or depression among others. Typically increased bleeding occurs with submucosal fibroids due to an increased endometrial surface and a resultant larger bleeding area (6). Symptoms related to pelvic pressure vary based on location, with fibroids in the anterior lower uterine segment typically responsible for symptoms of urinary frequency from compression of the bladder. Posterior fibroids may be responsible for symptoms of constipation due to pressure on the rectum. Pain is also a common symptom related to increased pelvic pressure and can often be associated with a low grade fever, tenderness, and elevated white blood cell count. Fibroids may also be responsible for increased complications during pregnancy. Women with fibroids during pregnancy may experience an increased risk of abruptio placentae, premature labor, miscarriage, and breech presentation at birth (7, 8).



## **Medical Management**

Medical therapy is not the mainstay of treatment and is primarily used for relief of symptoms or as a bridging treatment prior to surgery. Currently several pharmacotherapies exist which may provide temporary relief of symptoms. However, discontinuation of medical therapy often results in a rapid return of symptoms. The current mainstay of medical treatment involves the use of gonadotropin releasing hormone agonists as a hormone suppressive therapy. The gonadotropin releasing hormone agonists act to reproduce a pharmacological state of menopause by initially increasing the release of gonadotropins followed by a downregulation leading to a hypogonadal state (9). In most cases, treatment with gonadotropin releasing hormone agonists results in a reduction in uterine bleeding and a return to baseline of hematologic labs. Treatment also reduces fibroid size in most cases and can effectively manage symptoms of pelvic discomfort (10). Common side effects with gonadotropin releasing hormone agonists include osteoporosis, hot flashes, vaginal dryness, and transient frontal headaches (11). Reports of decreased bone density have also been reported leading to osteoporosis (10).

While the use of gonadotropin releasing hormone agonists do not constitute an effective primary therapy, their use prior to surgery as an adjunct therapy has considerable benefit in certain cases (11). In women undergoing myomectomy for fibroids, the use of gonadotropin release hormone agonists may permit a smaller incision, or for women undergoing hysterectomy, may allow vaginal hysterectomy due to a reduction in uterine and fibroid size. In women with considerable blood loss secondary to fibroids, the use of gonadotropin releasing hormone agonist may also allow for a return in hematocrit over time alleviating the need for blood transfusion (12).

## **Surgical Management**

As mentioned, surgery is the mainstay of treatment for uterine fibroids. Surgery is indicated in cases of symptomatic uterine fibroids not adequately controlled by more conservative treatment or in cases where a high suspicion of malignancy exists. Other indications for surgical management include growth of uterine fibroids following menopause, infertility related to tubal obstruction, or recurrent pregnancy loss (13). Several options exist for surgical management including total hysterectomy, myomectomy, and several newer procedures, such as uterine artery occlusion, and uterine artery embolization.

## **Hysterectomy**

Currently in the United States more than 600,000 hysterectomies are performed per year (14). Nearly a quarter to a third of the hysterectomies performed in the United States are performed for symptomatic uterine fibroids (15). The advantage of classic hysterectomy includes relief from symptomatic uterine fibroids, as well as eliminating the chance of recurrence. A recent study following 1,299 women found that over 90% of the women noticed improved quality of life, decreased symptoms, and decreased depression two years after hysterectomy (16). Hysterectomy is also indicated over other surgical procedures when a high suspicion of malignancy exists or in patients with extensive fibroids not amenable to myomectomy. In the absence of these factors, issues concerning uterine conservation and future child-bearing should be addressed when considering between the available options.

While the overall mortality rate with hysterectomy is quite low, this procedure is not without complications. Complications that are seen most often include incontinence,

vaginal vault prolapse, and risk of premature ovarian failure (17). Incontinence secondary to urinary tract injuries during surgery often occur most commonly in cases where uterine fibroids extend into the broad ligament, compress the bladder, or extend deep into the pelvis (13).

### **Myomectomy**

Myomectomy is a surgical alternative to hysterectomy and allows for the preservation of the uterus along with the possibility of future pregnancies. In cases involving a solitary pedunculated fibroid, myomectomy is also the preferred surgical treatment. Although myomectomy is an effective therapy for menorrhagia and pelvic pressure, the disadvantage of this procedure is the significant risk that fibroids will re-occur. While hysterectomy eliminates the reoccurrence of fibroids, according to a recent meta-analysis study, fibroids may reoccur in nearly 20-50% of cases 5 years after myomectomy (18).

### **Hysteroscopic Myomectomy**

Submucosal fibroids can be removed by a procedure known as hysteroscopic myomectomy. This procedure utilizes the submucosal location of fibroids to enter the cervix without an incision using a specialized scope that can cut and coagulate tissue from within the cavity. Compared to abdominal myomectomy, hysteroscopic myomectomy offers several advantages including the use of local anesthetic versus general anesthesia. Hysteroscopic myomectomy is also an outpatient procedure with a short recovery period. As described in a large prospective study of 156 women followed over 9 months after hysteroscopic myomectomy, fewer than 16% of women underwent a subsequent procedure for recurrent menorrhagia (19). For women considering pregnancy, hysteroscopic

myomectomy offers excellent fertility rates with a very low complication rate. In one study of 23 patients with associated infertility, pregnancy was achieved in eight cases following hysteroscopic myomectomy (20).

### **Laparoscopic Uterine Artery Occlusion**

Uterine artery occlusion is performed as a laparoscopic procedure in which the uterine arteries supplying the dominant fibroids are occluded. The advantage of this procedure compared to uterine artery embolization is that this approach allows for thorough and direct examination of the pelvis and avoids the use of foreign material such as embolization agents into the body. However a disadvantage of this procedure over uterine artery embolization is that it is still a surgical approach requiring general anesthesia.

### **Uterine Artery Embolization**

Uterine artery embolization (UAE) was first reported as a successful treatment for life-threatening gynecologic bleeding in 1979 (21, 22). Since this initial successful intervention, UAE has been reported as a successful procedure in the control of bleeding from a variety of different sources including tumors and traumatic pelvic injuries (23-25). The first use of UAE for symptomatic uterine fibroids was reported in 1994 (26) and given the relative lack of complications and relatively high success rates reported in initial cases, research into uterine fibroid embolization (UFE) as a possible treatment for symptomatic uterine fibroids continued (27-29).

### **Indication for Embolization**

Compared to hysterectomy and medical treatment, uterine fibroid embolization is a relatively new procedure. To date, no absolute criteria exist for the indication to perform

UFE. From the literature the most common indications to perform UFE include contraindications to surgery and recurrent fibroids following alternative therapies such as myomectomy (30). In the management of uterine fibroids prior to considering UFE, a thorough gynecological workup must be performed in order to consider relevant differential diagnoses such as endometrial polyps, leiomyosarcoma, focal contractions of the myometrium, and extrauterine findings (e.g., ovarian tumors), all of which are absolute contraindications for UFE. In addition to a thorough gynecological workup, further imaging studies should be obtained prior to performing UFE to provide more detailed information regarding type, size, and exact number of fibroids. MRI is the preferred imaging modality allowing a detailed overview of the pelvic anatomy along with the ability to differentiate carcinomas of the endometrium, adenomyosis, and different types of fibroids (31, 32).

It is unclear whether adenomyosis represents an absolute contra-indication to UFE, several reports describe circumstances where patients with adenomyosis do not improve symptomatically after UFE (33, 34). However, a single study in the literature reports improvement of clinical symptoms in adenomyosis after UFE (35). Other relative contraindications for UFE include non-growing fibroids in menopausal women or in postmenopausal women with atypical bleeding, along with pedunculated or very large fibroids extending above the level of the umbilicus (30). Absolute contra-indications for UFE in addition to those listed above include fibroids with a very thin pedicle, infection of the genital tract, and contra-indications to contrast dyes.

### **Technique of Embolization**

Uterine fibroid embolization (UFE) involves the placement of a catheter and the injection of embolization agent into the dominant artery or arteries that supply the uterine fibroids. Typically access is obtained through a femoral access route, then traversing the internal iliac artery to the uterine artery. Most fibroids due to the dual supply of the uterus from both uterine arteries are also supplied by both uterine arteries, necessitating embolization of both uterine arteries (36, 37). However, arteriography before embolization is necessary to exclude any additional supplying arteries or aberrant arterial malformations.

In general UFE takes advantage of the fact that uterine fibroids are typically supplied by high flow arterial branches of the uterine arteries. This is in stark contrast to the normal myometrium, which tends to be supplied by low flow arterial branches of the uterine arteries. The difference in flow rates of the arteries supplying the fibroids versus the normal myometrium allows placement of the catheter delivering the embolization agent relatively proximal in the uterine artery with delivery of the embolization agent somewhat selectively to the branches supplying the fibroid or fibroids given their high flow state.

The choice of embolization agent is highly user dependent with choices ranging from polyvinyl alcohol particles, gelfoam, and stainless steel coils, to tris-acryl gelatin microspheres. To date there exists no consensus on the most effective embolization agent, however a recent study noted that the use of spherical polyvinyl alcohol particles led to a particularly high rate of failed fibroid tumor infarction (38). Additionally, no consensus exists on the ideal size of embolizing particles, with reports suggesting success with particle sizes ranging from 150-500  $\mu\text{m}$  to 500-710  $\mu\text{m}$  (39-41). Some reports have

suggested that smaller embolization particles may result in a greater overall decrease in size of fibroids, however an increase in the rate of complications notably ovarian and cervical ischemia (40).

### **Results of Embolization**

Following uterine fibroid embolization, technical success rates vary from 85% to 100% in most reported studies (42-44). Technical success is characterized by occlusion or marked reduction in the blood flow of both uterine arteries, and not by reduction in size of fibroids, or reduction of symptoms. Clinical success on the other hand involves parameters that include the reduction in size of fibroids, reduction of patient symptoms, and patient satisfaction. The range of overall reduction in dominant fibroid size seems to vary between 42% - 83%, with the largest reduction in overall fibroid size occurring during the first six months and an additional decrease over the next six months (27, 45, 46). Overall uterus size reduction post UFE varies from 43% - 58% (27, 45-47).

In contrast to reduction in fibroid volumes, relief of patient symptoms occurs with much higher frequency with a range of 86% - 94% and elimination of abnormal uterine bleeding in 88% - 96% of cases (30, 46-48). One such study, a randomized control trial comparing UFE to hysterectomy found the success rate of controlling abnormal bleeding after UFE to be 88.9% (17) consistent with another previous smaller randomized study (44).

### **Pregnancy after UFE**

While UFE does preserve the uterus in contrast to hysterectomy, there is much debate as to the safety of UFE in those women desiring future pregnancies. Currently in the literature there is only limited data regarding the outcome of pregnancies after UFE. While several

studies do report full term pregnancies following UFE, it may be at the cost of higher prepartum and post-partum complications (49-51). In a meta-analysis study of previously published cases of pregnancy following UFE for symptomatic fibroids, a 32% rate of spontaneous abortion was reported compared to a rate of 10-15% in the general population. A 22% rate of malpresentation was reported in post-UFE pregnancies vs. 5% in the general population, 22% rate of premature delivery vs. 5-10%, a 65% cesarean delivery rate vs. 22% in the general population, and a 9% rate of postpartum hemorrhage vs. 4-6% in the general population (52). The authors report a possibility for the increased malpresentation rate due to the presence of residual leiomyomata. In a recent study comparing the outcomes of pregnancy post UFE versus laparoscopic myomectomy, the rates of preterm delivery, malpresentation, postpartum hemorrhage, and spontaneous abortion were slightly higher in pregnancies following UFE, however these increased rates were not statistically significant (53).

### **Complications of Embolization**

Overall most case reports and studies suggest that UFE has a low complication rate and remains safe as an alternative to hysterectomy and myomectomy. A randomized control clinical trial comparing UFE to hysterectomy found intra-procedural complication rates to be similar between UFE and hysterectomy, 25% versus 20% respectively (44). However within the UFE group all events were categorized as minor complications consisting of arterial spasm, uterine artery dissection, or gluteal artery perforation. Whereas the complications within the hysterectomy group were all categorized as major complications with patients either needing transfusion or having had vesical fissure. Post-procedural complication rates between the two groups were 72% for UFE and 45% for patients who



underwent hysterectomy again with the majority of complications in UFE categorized as minor complications versus most of the complications being categorized as moderate and major complications in the hysterectomy group.

A large prospective 400 patient study followed UFE patients over 3 months for all adverse events and complications (54). These events and complications were then categorized according to the Society of Cardiovascular and Interventional Radiology complication classes, A through F, with severity of complications increasing from minor complications, class A, to major, severe complications comprising class F. Minor complications listed as class A and B occurred in 10.5% of patients with the most common complication listed as allergic reaction. Other complications within this category included fibroid passage, hematoma, urinary tract infection, femoral nerve injury, urinary retention, deep venous thrombosis, and *clostridium difficile* infection. Class C complications were encountered in 2.5% of patients. These included four hospitalizations for pain control, four for fibroid passage, and two hospitalizations for endometritis. Of the five patients (1.25%) that had class D complications, the first patient was diagnosed with a pulmonary embolus, the second patient developed bilateral iliac artery thrombosis that was treated with thrombolytic therapy. The third patient was hospitalized for a uterine infection 10 weeks after embolization secondary to fibroid tissue passage, while the fourth patient had a similar infection requiring hysteroscopic removal of the fibroid tissue. The fifth patient had extensive bleeding secondary to fibroid passage 4 months following embolization, which required a hysterectomy after dilation and curettage failed to control the bleeding. There were no reported class E or class F complications within this study and no reported deaths.

While not reported in the previously mentioned study, another important, however rare, complication includes ovarian failure after UFE. Reported rates of ovarian failure after UFE range from 1-2% (43) and are likely secondary to unintended embolization of the ovaries via utero-ovarian anastomoses (55).

Death is also a complication not readily considered given the very low rates of occurrence. Currently there are three reported deaths documented in the literature following UFE, two of these cases involving pulmonary embolus, and the last death as a result of infection (56, 57).

*Chapter 2*

## STATEMENT OF PURPOSE

The purpose of this study is to first classify uterine fibroids based on MR image border appearance of either the smooth or lobulated variety. Currently no such system exists to categorize uterine fibroids based on appearance. The utility of this categorization is to add another variable by which to analyze the factors that may play an important role in determining fibroids that are more responsive to uterine fibroid embolization (UFE). While no good criteria exist for the evaluation of fibroids amenable to treatment by embolization, our goal was to evaluate factors of fibroid location, and border appearance to determine if any of these criteria could be used as predictive factors for responsiveness to UFE. Using existing data classifying outcomes of patients undergoing UFE, we will attempt to correlate our categorization of uterine fibroid appearance on MRI to outcomes and MR images post-embolization.

Our hypothesis is that a difference exists between the two categories of uterine fibroids seen on MRI to the rate of responsiveness following UFE and that fibroids characterized as lobulated respond much better to embolization than fibroids characterized as smooth in border appearance. While no previous literature exists characterizing fibroids based on smooth versus lobulated border criteria, there exists some literature describing variances in fibroid signal intensity based on differing pathology. Our hypothesis stems from the possibility that fibroids characterized as either smooth or lobulated may exhibit varying pathology and thus respond differently to embolization.

## Specific Aims

1. Evaluate pre-embolization MR images of patients with uterine leiomyomas and characterize the uterine leiomyoma based on border appearance as well as location.
2. Evaluate pre-embolization and post-embolization MR images to determine outcomes data based on uterine and leiomyoma volume changes.
3. Correlate the categorization of uterine leiomyoma with outcomes data to determine if border characteristics play a role in predicting success in uterine fibroid embolization.
4. Analyze data concerning location of uterine leiomyoma to determine what role if any location plays in overall response to uterine fibroid embolization.

*Chapter 3*

## MATERIALS AND METHODS

This study consists of women evaluated for evidence of uterine fibroids and referred to the Yale Interventional Radiology group. Two hundred women were treated with uterine fibroid embolization (UFE) for symptomatic fibroids and enrolled in an already HIC approved study looking at other outcomes data for embolization.

MRI images were obtained before and after UAE in 35 women. These images were analyzed for uterine and fibroid size changes along with fibroid border characteristics and location for a total of 73 fibroids.

**Embolization**

An experience angiographer (MJT) performed bilateral UFE in each patient. A variety of embolization agents were used and recorded for each case, with the dominant embolization agent being polyvinyl alcohol particles. The institutional review board gave approval for the entire study, and each patient gave written informed consent. Patients received pre-procedural MR images prior to UFE. Patients were seen in clinic and evaluated 6 months post-operatively for follow-up. MR images were obtained at this time to observe any change in fibroid and uterine size.

**Image Evaluation**

Two readers (TP and SD) independently analyzed MR images for each UFE patient. Pre-procedural images were used and each reader was given T1 and T2 weighted and gadolinium enhanced composite images of the uterus and uterine fibroids. Both readers

were blinded to outcome and post-procedural MR images of each case. Within each image, T2 fat saturated images were primarily used to ascertain border criteria of each fibroid. Fibroids measured to be <3 cm in any diameter were excluded from this study. For each fibroid >3cm, the border was described as either smooth or lobulated based on images that were defined as standards for each category (see Figure 1). Results were compared and any discrepancies in results were shown to an independent third reader (MJT) for analysis and categorization. Each fibroid was also evaluated for separate criteria including location and size. The size of each fibroid was measured both in the pre-procedural MR image and in the follow-up MR image post-procedure. The degree of enhancement in the post-procedural MR image was also evaluated for each fibroid. The dimensions of the uterus were also measure for each pre-procedural MR image and post-procedural MR image.

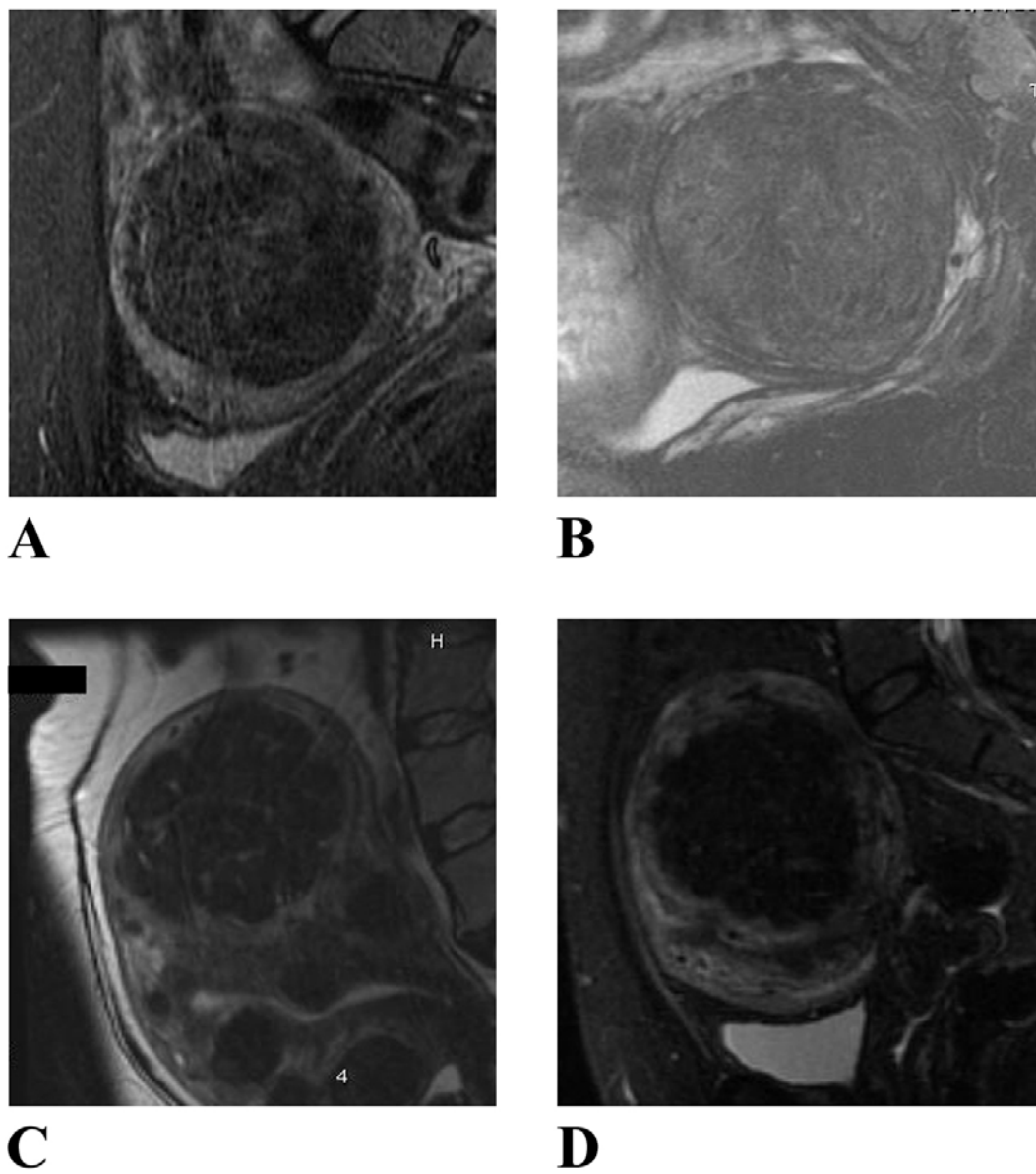


Figure 1. T2 fat saturated, midsagittal MR Images. Images are references for determination and categorization of uterine leiomyoma into smooth (A, B) and lobulated (C, D) based on border appearance.

### **Data Analysis**

The data gathered from each image were placed into an existing database containing dates of pre and post – procedural films along with embolization agent used. The volume for each fibroid was calculated using the equation for a sphere or prolate ellipse (length \* width \* height \* 0.523). The volume of each uterus was also determined using a prolate ellipse equation (length \* width \* height \* 0.523) for each pre-procedural MR image and post-procedural MR image. The absolute volume change and percentage change for each uterus and fibroid was determined with a determination of averages between the fibroids categorized as either smooth or lobulated. Using a statistical analysis program (SAS) the absolute and percentage volume changes were subjected to an Analysis of Variance (ANOVA) test to determine *p*-values. Also inter-patient variance was determined using a fisher t-test.

### **Contribution**

My contributions to the project were primarily focused on analyzing and interpreting both the pre-operative and post-operative MR images for each patient along with much of the statistical analysis performed. Out of the nearly 200 uterine fibroid embolizations (UFE), I was present for only a fraction of the cases seen in follow-up clinic. Specifically using an already established database containing patient names and dates of embolization along with other data points, I analyzed each MR image for every patient listed in the database. I categorized each dominant fibroid as to whether the border was either smooth or lobulated and merged this information with the existing database. Working with the MR imaging



fellow, we were able to measure and mark the location of each fibroid in the pre-operative and post-operative images. I entered this data as well into the database and tabulated the calculated fibroid and uterine volumes. After all of the imaging data were collected, I reformatted the data to be used in a statistical modeling program (SAS) and subsequently ran the data through multiple variances of the t-test and ANOVA test.

## Chapter 4

### RESULTS

MRI images were obtained before and after UAE in 35 women. These images were analyzed for uterine and fibroid size changes along with fibroid border characteristics and location for a total of 73 fibroids.

#### **Volume Changes**

From the analysis of pre-embolization MR images from 35 women, the average uterine volume was  $656.6 \text{ cm}^3 \pm 590.6 \text{ cm}^3$  (SD). The average fibroid volume ( $n= 73$ ) prior to embolization was  $125.6 \text{ cm}^3 \pm 203.9 \text{ cm}^3$  (SD). After embolization, the average uterine volume was  $356.7 \text{ cm}^3 \pm 305.2 \text{ cm}^3$  (SD). This resulted in an average decrease of  $35.7\% \pm 24.9\%$  (SD) from pre-embolization uterine volume to post-embolization volume ( $P < 0.001$ ). The mean fibroid volume post-embolization was  $57.6 \text{ cm}^3 \pm 85.8 \text{ cm}^3$  (SD), resulting in an average decrease of  $48.1\% \pm 28.6 \%$  (SD) from pre- to post-embolization volume ( $P < 0.001$ ). The mean elapsed time between pre-embolization and post-embolization MR images was approximately 38 weeks and 5 days.

#### **Prognostic Features**

Two categories of prognostic features were analyzed, border appearance and location. Border appearance was described as either smooth or lobulated. Approximately 29.3% of fibroids were lobulated ( $n= 22$ ) with an average volume of  $237.5 \text{ cm}^3 \pm 203.9 \text{ cm}^3$  (SD) pre-embolization and an average volume of  $129.4 \text{ cm}^3 \pm 101.2 \text{ cm}^3$  (SD) post-embolization. Fibroids categorized as smooth comprised 70.7% ( $n= 53$ ) of the total fibroids

with an average volume of  $83.4 \text{ cm}^3 \pm 189.1 \text{ cm}^3$  (SD) pre-embolization and an average volume of  $30.5 \text{ cm}^3 \pm 70.0 \text{ cm}^3$  (SD) post-embolization. The average volume change in lobular fibroids from pre-embolization volume to post-embolization volume was  $108.1 \text{ cm}^3 \pm 143.0 \text{ cm}^3$  (SD) resulting in a reduction of  $40.6\% \pm 23.1\%$  (SD). In fibroids characterized as smooth, the average volume change from pre-embolization to post-embolization was  $52.9 \text{ cm}^3 \pm 164.9 \text{ cm}^3$  (SD) resulting in a reduction of  $50.9\% \pm 30.2\%$  (SD).

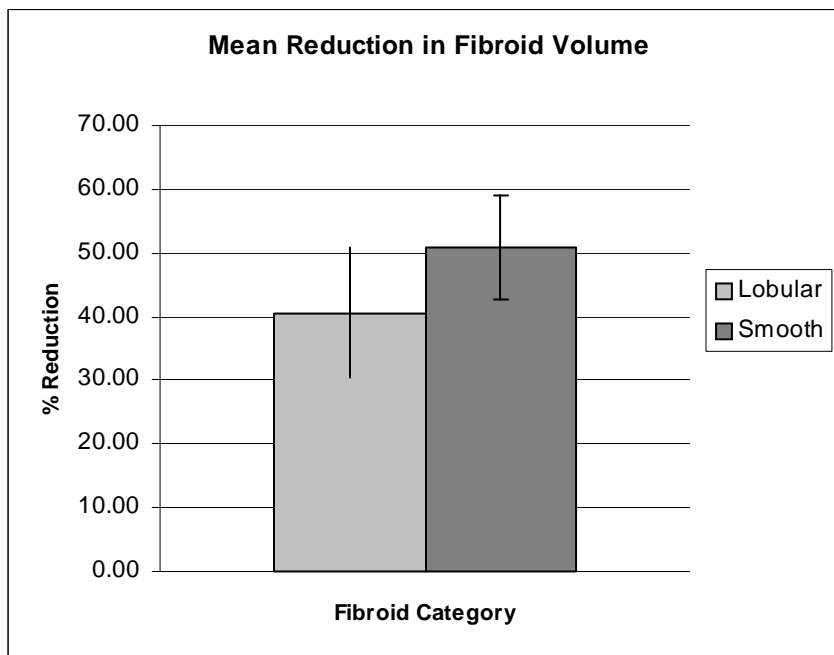


Figure 2. Graph shows a comparison of mean reduction in fibroid volume before and after embolization between lobulated and smooth fibroids. Error bars indicate 95% confidence intervals for each group.

The calculated confidence interval for the mean change in volume between lobulated and smooth fibroids is  $[-25.1, 4.6, \text{SEM } 7.5, \text{Df } 71]$ . Since this interval includes zero, the possibility that both mean volume changes may be equal exists, and we cannot conclude

that there is statistical difference between the mean volume changes in both groups. Single factor ANOVA demonstrated no appreciable difference of mean volume change between the two groups ( $F [1,71]= 1.88$ ,  $F_{crit}= 3.98$ ,  $p= 0.17$ ). However if we define failure of embolization as no reduction or increase of fibroid volume from pre-embolization to post-embolization, there was a single failure within the lobulated fibroids for a failure rate of 5%. Within fibroids categorized as smooth, there were a total of five failures for a failure rate of 9.4%. Single factor ANOVA demonstrated some difference between the two groups when looking at failure rate, however with low statistical power ( $F [1, 71]= 0.37$ ,  $F_{crit}= 3.98$ ,  $p= 0.26$ ).

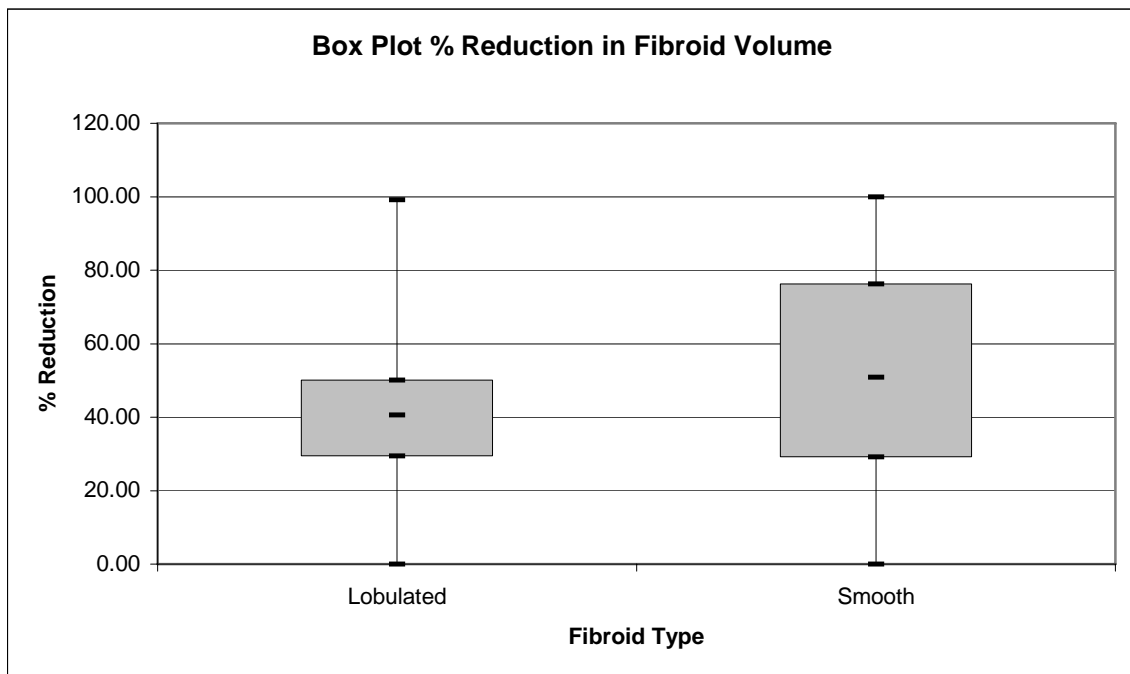


Figure 3. Graph illustrates a comparison of pre-embolization and post-embolization fibroid volume reduction in fibroids between smooth and lobulated fibroids. Box plots show median (middle line of box), first quartile (bottom line of box), third quartile (top line of box), minimum values (lower whisker), and maximum values (upper whisker).

Similar results were obtained when looking at location as a prognostic indicator. While there was some difference between the groups, there was little statistical power to indicate with certainty that location is a prognostic factor in determining outcome after embolization. Approximately 64.4% of fibroids were intramural (n= 47), 12.3% submucosal (n= 9), and 23.3% subserosal (n= 17). The mean pre-embolization volume for intramural fibroids was  $155.1 \text{ cm}^3 \pm 218.7 \text{ cm}^3$  (SD) with a mean post-embolization volume of  $65.2 \text{ cm}^3 \pm 86.0 \text{ cm}^3$  (SD). The mean pre-embolization volume for submucosal fibroids was  $127.2 \text{ cm}^3 \pm 276.5 \text{ cm}^3$  (SD) with a mean post-embolization volume of  $71.6 \text{ cm}^3 \pm 138.7 \text{ cm}^3$  (SD). The mean pre-embolization volume for subserosal fibroids was  $43.3 \text{ cm}^3 \pm 41.0 \text{ cm}^3$  (SD) with a mean post-embolization volume of  $29.1 \text{ cm}^3 \pm 32.8 \text{ cm}^3$  (SD). The average change in volume from pre-embolization volume to post-embolization volume in each of the groups was  $89.8 \text{ cm}^3 \pm 186.2 \text{ cm}^3$  (SD),  $55.6 \text{ cm}^3 \pm 148.5 \text{ cm}^3$  (SD),  $14.3 \text{ cm}^3 \pm 12.0 \text{ cm}^3$  (SD) respectively for intramural, submucosal, and subserosal fibroids for a reduction in volume of  $51.6\% \pm 30.2\%$  (SD) in intramural fibroids,  $43.9\% \pm 29.4\%$  (SD) in submucosal fibroids, and  $40.6\% \pm 22.9\%$  (SD) in subserosal fibroids. Single factor ANOVA demonstrated no appreciable difference of mean volume change between the three groups ( $F [2,70]= 1.04$ ,  $F_{\text{crit}}= 3.13$ ,  $p > 0.2$ ).

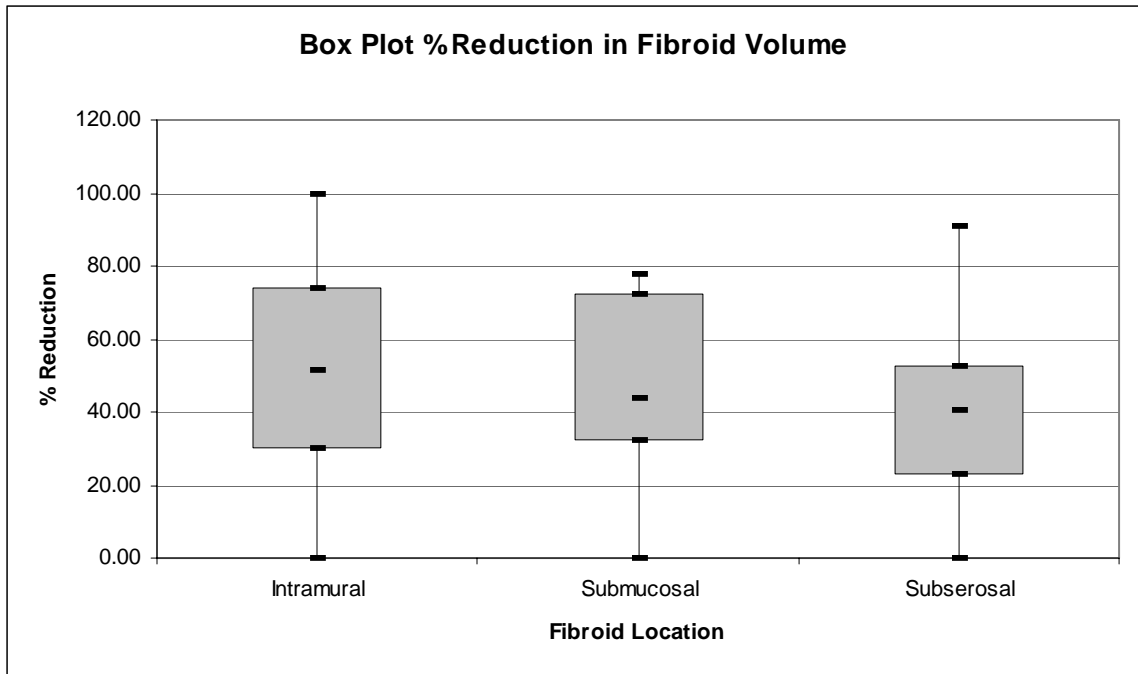


Figure 4. Graph illustrates a comparison of pre-embolization and post-embolization fibroid volume reduction in fibroids of different locations. Box plots show median (middle line of box), first quartile (bottom line of box), third quartile (top line of box), minimum values (lower whisker), and maximum values (upper whisker).

## Chapter 5

### DISCUSSION

#### **Discussion**

Findings from this study do not clearly demonstrate a significant difference in volume reduction between fibroids categorized as either lobulated or smooth on MR imaging. While some minor differences are noted, the low statistical power does not allow us to draw a distinct conclusion. Similarly, findings from this study do not suggest a significant difference in volume reduction of fibroids post-embolization based upon fibroid location. Our study does suggest some minor difference when looking at overall embolization failure rate rather than volume changes between smooth and lobulated fibroids, albeit again with low statistical power.

#### *Uterine volumes*

Clearly the relative change in uterine volume relative to fibroid type is not of statistical significance. Uterine volume as a measurement of embolization success is an inaccurate predictor of overall success given that uterine volume changes in accordance to a variety of factors. When measuring uterine volumes post-embolization, relative changes in fibroids seen on the pre-procedural MR image are measured along with fibroids that may not have been seen at the time of the initial MR image that have since increased in size. Thus overall uterine volume is not an accurate predictor of embolization success and although useful cannot be used to ascertain predictive factors that determine outcome. The usefulness of uterine volume changes in determining the differences between smooth and lobulated

fibroids is also confounded by the fact that in some of the patients, multiple fibroids of both varieties were present, rendering the uterine volume change useless in those patients.

#### *Fibroid volumes*

While uterine volume change is not an accurate assessment of success following embolization, individual fibroid volume changes are an accurate measurement of response following embolization. Previous studies investigating predictive factors correlating to embolization success have used a variety of findings to measure success including ultrasonography and improvement in physical symptoms. MR provides an improved accuracy over ultrasonography and a much simpler measure of success over improvement in physical symptoms. The value of improvement in clinical symptoms is certainly important following embolization, however there is such variability in assessing such criteria that it becomes very difficult to ascertain a true measure of success given the subjective nature of obtaining patient history. Several studies have validated the use of MR characteristics as a measurement of success following embolization (58).

There was a significant reduction in mean uterine fibroid volumes in our study. This result is consistent with the 45%-65% range of mean uterine fibroid volume reduction reported in other studies (33). Our results showed that there was little difference in the overall reduction of fibroid volumes between smooth and lobulated fibroids, with little statistical power suggesting a strong difference in response. It is unclear why on average fibroids of the lobulated variety were nearly three times the size of the smooth variety. Not all large fibroids were of the lobulated variety and not all small fibroids were of the smooth variety. Whether this size difference confounds our data regarding the overall percentage change in fibroids post-embolization is also unclear. There has been some speculation that larger



uterine volumes and larger fibroid volumes may exhibit varying responses to embolization secondary to embolization particle distribution (59). Also a greater number of embolization particles may be required for larger fibroids, rather than current protocols that do not titrate embolization particles based on size of uterus or fibroids.

### *Predictive Factors*

Despite the relative lack of difference in fibroid volume change between the two groups, when looking at failure defined as an increase in fibroid size after embolization there was a trend towards a difference between the two groups. Only one fibroid within the lobulated category increased in size post-embolization representing a 5% failure rate. This is in contrast to the fibroids categorized as smooth which had a near 10% failure rate, with five fibroids showing an increase in size after embolization. It is hard to draw a definite conclusion based on this result in the absence of correlation based on overall mean fibroid volume change between the two groups, however it does suggest some fundamental difference between fibroids classified as either smooth or lobulated. Whether this difference extends to the level of pathology is unclear and certainly warrants further investigation. Previous studies suggest different cellular pathology for fibroids exhibiting varying signal intensity levels on MR, with high signal intensity fibroids composed of compact smooth muscle cells compared to fibroids exhibiting decreased signal intensity due to uniform smooth muscle cells with various amounts of intervening collagen (60, 61). Perhaps lobulated fibroids exhibit similar disparities on pathology compared to fibroids with a smooth border appearance, to date there exists no literature mentioning any characteristics of either smooth or lobulated fibroids.

While the main focus of this study was the categorization of fibroids based on MR image appearance, the data allow for other factors to be independently analyzed. The location and type of each fibroid was noted for use as a possible predictor of outcome post-embolization. While not thoroughly characterized, some studies have concluded that submucosal fibroids have a strong correlation to positive outcomes as compared to intramural and subserosal fibroids (59). Our study found no real correlation between location of fibroid and change in fibroid volume after embolization.

#### *Limitations of the study*

While every step was taken to ensure that the data gathered were accurate and not misrepresented, every study has certain limitations that must be considered when drawing a conclusion regarding data presented within the study. Certainly as is true for many studies, sample size plays a large role in the power of a study. In our case, while the sample size is quite large, there is still not enough data regarding the non-responders to embolization. Given that success rates of embolization in regards to overall reduction of fibroid size vary from 42% to 83% (27, 45, 46), and in our study roughly 90%, the total sample size of cases in which fibroids did not respond to embolization is very low. Naturally, increasing the sample size and thus increasing the number of cases in which failure occurred would add statistical power to the study to analyze factors that play a role in determining non-responders to embolization.

Several other potential sources of error play a role in determining the conclusions that can be drawn from this study. One large source of error comes from the subjective nature of determining the characteristic of the fibroid border. Since categorizing fibroids as either lobulated or smooth is not a readily quantifiable measurement, this introduces a source

potential error. While an attempt to minimize this error was made by having two independent readers categorize each fibroid and a third reader to rectify any discrepancy, this cannot be ruled out as a potential source of error. Another limitation of this study is the inability to factor many of the other variables that may have played a role in the outcomes of both fibroid and uterine volumes after embolization. These factors include the relative location of each fibroid as well as the presence of adenomyosis. As mentioned the role of embolization in patients with adenomyosis is unclear. Several studies report no improvement in patients with adenomyosis (33, 34), whereas a single recent study does report improvement after embolization (35). It is unclear what role adenomyosis plays in the reduction of individual fibroid and uterine size post-embolization. In our study we were unable to distinguish between patients with adenomyosis from those without adenomyosis. Another factor that was not accounted for in this study was the choice of embolization agent used for each patient. While the dominant embolization agent was polyvinyl alcohol particles, the choice of embolization agent and resultant outcome based on agent used was not determined. However based upon the single patient variance studies, the variability of embolization agent used would not play a role.

Lastly, while the majority of fibroids decrease in size the greatest over the first 6 months post-embolization (46), not all fibroids decrease at the same rate. Ideally follow-up images would be obtained at identical times post-embolization for each patient and at multiple time points, however in reality this is not technically feasible given the variability in availability of imaging resources and the incapacity to obtain multiple MR images for a large patient sample. In our study there was some variability between each patient in the length of time

that images were obtained post-embolization. This variability could have played some role in the overall measurement of reduction in both fibroid and uterine volumes.

Despite the potential limitations of this study, the data provide some interesting conclusions in the response of fibroids to embolization and warrant further investigation into the potential differences that contribute to the appearance on MR imaging of fibroids as either smooth or lobulated and what differences, if any, there are in response to embolization.

### **Conclusion**

Currently uterine fibroid embolization (UFE) is a viable treatment option for women experiencing symptomatic uterine fibroids not wanting to undergo hysterectomy. While the overall success rate of UFE is very good, there exist a small percentage of women who do not benefit from UFE. However, to date no reliable criteria exist regarding the prediction of outcomes amongst women undergoing UAE for uterine fibroids. Size of fibroids has been in some studies implicated as a predictive factor (43, 47), however this finding has not been consistent throughout studies looking at predictive factors (30, 58). A predictive factor that would classify uterine leiomyomas as either likely responders or non-responders would be of great use in determining proper pre-embolization candidates and likely increase the overall response rate in UAE as well as overall patient satisfaction.

We introduced a novel characteristic by which to classify uterine fibroids based upon border appearance on MR imaging in the hopes of elucidating what role, if any, border appearance has on outcomes following embolization. Although we were not able to show a significant difference in volume reduction between those fibroids categorized as either lobulated or smooth, we were able to note an albeit small difference in embolization failure

rates between smooth and lobulated fibroids. Further, our analysis did not reveal any difference based upon fibroid location in overall volume reduction after embolization.

*Chapter 6*

## BIBLIOGRAPHY

1. Day Baird, D., Dunson, D.B., Hill, M.C., Cousins, D., and Schectman, J.M. 2003. High cumulative incidence of uterine leiomyoma in black and white women: ultrasound evidence. *Am J Obstet Gynecol* 188:100-107.
2. Kjerulff, K.H., Langenberg, P., Seidman, J.D., Stolley, P.D., and Guzinski, G.M. 1996. Uterine leiomyomas. Racial differences in severity, symptoms and age at diagnosis. *J Reprod Med* 41:483-490.
3. Ross, R.K., Pike, M.C., Vessey, M.P., Bull, D., Yeates, D., and Casagrande, J.T. 1986. Risk factors for uterine fibroids: reduced risk associated with oral contraceptives. *Br Med J (Clin Res Ed)* 293:359-362.
4. Marshall, L.M., Spiegelman, D., Goldman, M.B., Manson, J.E., Colditz, G.A., Barbieri, R.L., Stampfer, M.J., and Hunter, D.J. 1998. A prospective study of reproductive factors and oral contraceptive use in relation to the risk of uterine leiomyomata. *Fertil Steril* 70:432-439.
5. Treloar, S.A., Martin, N.G., Dennerstein, L., Raphael, B., and Heath, A.C. 1992. Pathways to hysterectomy: insights from longitudinal twin research. *Am J Obstet Gynecol* 167:82-88.
6. Buttram, V.C., Jr., and Reiter, R.C. 1981. Uterine leiomyomata: etiology, symptomatology, and management. *Fertil Steril* 36:433-445.
7. Exacoustos, C., and Rosati, P. 1993. Ultrasound diagnosis of uterine myomas and complications in pregnancy. *Obstet Gynecol* 82:97-101.
8. Salvador, E., Bienstock, J., Blakemore, K.J., and Pressman, E. 2002. Leiomyomata uteri, genetic amniocentesis, and the risk of second-trimester spontaneous abortion. *Am J Obstet Gynecol* 186:913-915.
9. Shalev, E., and Leung, P.C. 2003. Gonadotropin-releasing hormone and reproductive medicine. *J Obstet Gynaecol Can* 25:98-113.
10. Minaguchi, H., Wong, J.M., and Snabes, M.C. 2000. Clinical use of nafarelin in the treatment of leiomyomas. A review of the literature. *Journal of Reproductive Medicine* 45:481-489.
11. Letterie, G.S., Coddington, C.C., Winkel, C.A., Shawker, T.H., Loriaux, D.L., and Collins, R.L. 1989. Efficacy of a gonadotropin-releasing hormone agonist in the treatment of uterine leiomyomata: long-term follow-up. *Fertility & Sterility* 51:951-956.

12. Stovall, T.G., Muneyyirci-Delale, O., Summitt, R.L., Jr., and Scialli, A.R. 1995. GnRH agonist and iron versus placebo and iron in the anemic patient before surgery for leiomyomas: a randomized controlled trial. Leuprolide Acetate Study Group. *Obstetrics & Gynecology* 86:65-71.
13. Wallach, E.E., and Vlahos, N.F. 2004. Uterine Myomas: An Overview of Development, Clinical Features, and Management. *Obstet Gynecol* 104:393-406.
14. Wilcox, L.S., Koonin, L.M., Pokras, R., Strauss, L.T., Xia, Z., and Peterson, H.B. 1994. Hysterectomy in the United States, 1988-1990. *Obstet Gynecol* 83:549-555.
15. Lepine, L.A., Hillis, S.D., Marchbanks, P.A., Koonin, L.M., Morrow, B., Kieke, B.A., and Wilcox, L.S. 1997. Hysterectomy surveillance--United States, 1980-1993. *MMWR CDC Surveill Summ* 46:1-15.
16. Kjerulff, K.H., Langenberg, P.W., Rhodes, J.C., Harvey, L.A., Guzinski, G.M., and Stolley, P.D. 2000. Effectiveness of hysterectomy. *Obstet Gynecol* 95:319-326.
17. Hehenkamp, W.J., Volkers, N.A., Donderwinkel, P.F., de Blok, S., Birnie, E., Ankum, W.M., and Reekers, J.A. 2005. Uterine artery embolization versus hysterectomy in the treatment of symptomatic uterine fibroids (EMMY trial): peri- and postprocedural results from a randomized controlled trial. *American Journal of Obstetrics & Gynecology* 193:1618-1629.
18. Fauconnier, A., Chapron, C., Babaki-Fard, K., and Dubuisson, J.B. 2000. Recurrence of leiomyomata after myomectomy. *Hum Reprod Update* 6:595-602.
19. Derman, S.G., Rehnstrom, J., and Neuwirth, R.S. 1991. The long-term effectiveness of hysteroscopic treatment of menorrhagia and leiomyomas. *Obstet Gynecol* 77:591-594.
20. Marziani, R., Mossa, B., Ebano, V., Perniola, G., Melluso, J., and Napolitano, C. 2005. Transcervical hysteroscopic myomectomy: long-term effects on abnormal uterine bleeding. *Clin Exp Obstet Gynecol* 32:23-26.
21. Heaston, D.K., Mineau, D.E., Brown, B.J., and Miller, F.J., Jr. 1979. Transcatheter arterial embolization for control of persistent massive puerperal hemorrhage after bilateral surgical hypogastric artery ligation. *AJR Am J Roentgenol* 133:152-154.
22. Oliver, J.A., Jr., and Lance, J.S. 1979. Selective embolization to control massive hemorrhage following pelvic surgery. *Am J Obstet Gynecol* 135:431-432.
23. Hausegger, K.A., Schreyer, H., and Bodhal, H. 2002. [Pelvic artery embolization in gynecological bleeding]. *Rofo* 174:809-818.
24. Velling, T.E., Brennan, F.J., Hall, L.D., and Watabe, J.T. 2000. Role of the interventional radiologist in treating obstetric-gynecologic pathology. *AJR Am J Roentgenol* 175:1273-1278.

25. Vedantham, S., Goodwin, S.C., McLucas, B., and Mohr, G. 1997. Uterine artery embolization: an underused method of controlling pelvic hemorrhage. *Am J Obstet Gynecol* 176:938-948.
26. Ravina, J.H., Merland, J.J., Herbreteau, D., Houdart, E., Bouret, J.M., and Madelenat, P. 1994. [Preoperative embolization of uterine fibroma. Preliminary results (10 cases)]. *Presse Med* 23:1540.
27. Ravina, J.H., Aymard, A., Ciraru-Vigneron, N., Ledreff, O., and Merland, J.J. 2000. [Arterial embolization of uterine myoma: results apropos of 286 cases]. *J Gynecol Obstet Biol Reprod (Paris)* 29:272-275.
28. Ravina, J.H., Merland, J.J., Ciraru-Vigneron, N., Bouret, J.M., Herbreteau, D., Houdart, E., and Aymard, A. 1995. [Arterial embolization: a new treatment of menorrhagia in uterine fibroma]. *Presse Med* 24:1754.
29. Ravina, J.H., Herbreteau, D., Ciraru-Vigneron, N., Bouret, J.M., Houdart, E., Aymard, A., and Merland, J.J. 1995. Arterial embolisation to treat uterine myomata. *Lancet* 346:671-672.
30. Helmberger, T.K., Jakobs, T.F., and Reiser, M.F. 2004. Embolization of uterine fibroids. *Abdominal Imaging* 29:267-277.
31. Bazot, M., Deux, J.F., Dahbi, N., and Chopier, J. 2001. [Myometrium diseases]. *J Radiol* 82:1819-1840.
32. Kawakami, S., Sagoh, T., Kumada, H., Kimoto, T., Togashi, K., Nishimura, K., Honda, H., Yamada, M., and Noguchi, M. 1991. Intravenous leiomyomatosis of uterus: MR appearance. *J Comput Assist Tomogr* 15:686-689.
33. Spies, J.B., Scialli, A.R., Jha, R.C., Imaoka, I., Ascher, S.M., Fraga, V.M., and Barth, K.H. 1999. Initial results from uterine fibroid embolization for symptomatic leiomyomata. *J Vasc Interv Radiol* 10:1149-1157.
34. Smith, S.J., Sewall, L.E., and Handelsman, A. 1999. A clinical failure of uterine fibroid embolization due to adenomyosis. *J Vasc Interv Radiol* 10:1171-1174.
35. Siskin, G.P., Tublin, M.E., Stainken, B.F., Dowling, K., and Dolen, E.G. 2001. Uterine artery embolization for the treatment of adenomyosis: clinical response and evaluation with MR imaging. *AJR Am J Roentgenol* 177:297-302.
36. McLucas, B., Reed, R.A., Goodwin, S., Rappaport, A., Adler, L., Perrella, R., and Dalrymple, J. 2002. Outcomes following unilateral uterine artery embolisation. *Br J Radiol* 75:122-126.
37. Bradley, E.A., Reidy, J.F., Forman, R.G., Jarosz, J., and Braude, P.R. 1998. Transcatheter uterine artery embolisation to treat large uterine fibroids. *Br J Obstet Gynaecol* 105:235-240.



38. Spies, J.B., Allison, S., Flick, P., Cramp, M., Bruno, J., Jha, R.C., and Ascher, S.A. 2005. Spherical polyvinyl alcohol versus tris-acryl gelatin microspheres for uterine artery embolization for leiomyomas: results of a limited randomized comparative study. *J Vasc Interv Radiol* 16:1431-1437.
39. Pelage, J.P., Laurent, A., Wassef, M., Bonneau, M., Germain, D., Rymer, R., Flaud, P., Martal, J., and Merland, J.J. 2002. Uterine artery embolization in sheep: comparison of acute effects with polyvinyl alcohol particles and calibrated microspheres. *Radiology* 224:436-445.
40. Siskin, G.P., Englander, M., Stainken, B.F., Ahn, J., Dowling, K., and Dolen, E.G. 2000. Embolic agents used for uterine fibroid embolization. *AJR Am J Roentgenol* 175:767-773.
41. Abulafia, O., and Sherer, D.M. 1999. Transcatheter uterine artery embolization for the management of symptomatic uterine leiomyomas. *Obstet Gynecol Surv* 54:745-753.
42. Hovsepian, D.M., Siskin, G.P., Bonn, J., Cardella, J.F., Clark, T.W., Lampmann, L.E., Miller, D.L., Omary, R.A., Pelage, J.P., Rajan, D., et al. 2004. Quality improvement guidelines for uterine artery embolization for symptomatic leiomyomata. *J Vasc Interv Radiol* 15:535-541.
43. Goodwin, S.C., McLucas, B., Lee, M., Chen, G., Perrella, R., Vedantham, S., Muir, S., Lai, A., Sayre, J.W., and DeLeon, M. 1999. Uterine artery embolization for the treatment of uterine leiomyomata midterm results. *J Vasc Interv Radiol* 10:1159-1165.
44. Pinto, I., Chimeno, P., Romo, A., Paul, L., Haya, J., de la Cal, M.A., and Bajo, J. 2003. Uterine Fibroids: Uterine Artery Embolization versus Abdominal Hysterectomy for Treatment--A Prospective, Randomized, and Controlled Clinical Trial. *Radiology* 226:425-431.
45. Walker, W.J., and Pelage, J.P. 2002. Uterine artery embolisation for symptomatic fibroids: clinical results in 400 women with imaging follow up. *Bjog* 109:1262-1272.
46. Pron, G., Bennett, J., Common, A., Wall, J., Asch, M., and Sniderman, K. 2003. The Ontario Uterine Fibroid Embolization Trial. Part 2. Uterine fibroid reduction and symptom relief after uterine artery embolization for fibroids. *Fertil Steril* 79:120-127.
47. Worthington-Kirsch, R., Spies, J.B., Myers, E.R., Mulgund, J., Mauro, M., Pron, G., Peterson, E.D., Goodwin, S., and Investigators, F. 2005. The Fibroid Registry for outcomes data (FIBROID) for uterine embolization: short-term outcomes.[erratum appears in *Obstet Gynecol*. 2005 Oct;106(4):869]. *Obstetrics & Gynecology* 106:52-59.

48. Hutchins, F.L., Jr., Worthington-Kirsch, R., and Berkowitz, R.P. 1999. Selective uterine artery embolization as primary treatment for symptomatic leiomyomata uteri. *J Am Assoc Gynecol Laparosc* 6:279-284.
49. Vashisht, A., Smith, J.R., Thorpe-Beeston, G., and McCall, J. 2001. Pregnancy subsequent to uterine artery embolization. *Fertil Steril* 75:1246-1248.
50. McLucas, B., Goodwin, S., Adler, L., Rappaport, A., Reed, R., and Perrella, R. 2001. Pregnancy following uterine fibroid embolization. *Int J Gynaecol Obstet* 74:1-7.
51. Ravina, J.H., Vigneron, N.C., Aymard, A., Le Dref, O., and Merland, J.J. 2000. Pregnancy after embolization of uterine myoma: report of 12 cases. *Fertil Steril* 73:1241-1243.
52. Goldberg, J., Pereira, L., and Berghella, V. 2002. Pregnancy After Uterine Artery Embolization. *Obstet Gynecol* 100:869-872.
53. Goldberg, J., Pereira, L., Berghella, V., Diamond, J., Darai, E., Seiner, P., and Seracchioli, R. 2004. Pregnancy outcomes after treatment for fibromyomata: uterine artery embolization versus laparoscopic myomectomy. *American Journal of Obstetrics and Gynecology* 191:18-21.
54. Spies, J.B., Spector, A., Roth, A.R., Baker, C.M., Mauro, L., and Murphy-Skrzynarz, K. 2002. Complications After Uterine Artery Embolization for Leiomyomas. *Obstet Gynecol* 100:873-880.
55. Payne, J.F., Robboy, S.J., and Haney, A.F. 2002. Embolic microspheres within ovarian arterial vasculature after uterine artery embolization. *Obstet Gynecol* 100:883-886.
56. Common, A.A., Mocarski, E.J., Kolin, A., Pron, G., and Soucie, J. 2001. Therapeutic failure of uterine fibroid embolization caused by underlying leiomyosarcoma. *J Vasc Interv Radiol* 12:1449-1452.
57. McLucas, B., Goodwin, S.C., Adler, L., and Reed, R. 1999. Fatal septicaemia after fibroid embolisation. *Lancet* 354:1730.
58. Burn, P.R., McCall, J.M., Chinn, R.J., Vashisht, A., Smith, J.R., and Healy, J.C. 2000. Uterine fibroleiomyoma: MR imaging appearances before and after embolization of uterine arteries. *Radiology* 214:729-734.
59. Jha, R.C., Ascher, S.M., Imaoka, I., and Spies, J.B. 2000. Symptomatic Fibroleiomyomata: MR Imaging of the Uterus before and after Uterine Arterial Embolization. *Radiology* 217:228-235.

60. Murase, E., Siegelman, E.S., Outwater, E.K., Perez-Jaffe, L.A., and Tureck, R.W. 1999. Uterine leiomyomas: histopathologic features, MR imaging findings, differential diagnosis, and treatment. *Radiographics* 19:1179-1197.
61. deSouza, N.M., and Williams, A.D. 2002. Uterine Arterial Embolization for Leiomyomas: Perfusion and Volume Changes at MR Imaging and Relation to Clinical Outcome. *Radiology* 222:367-374.